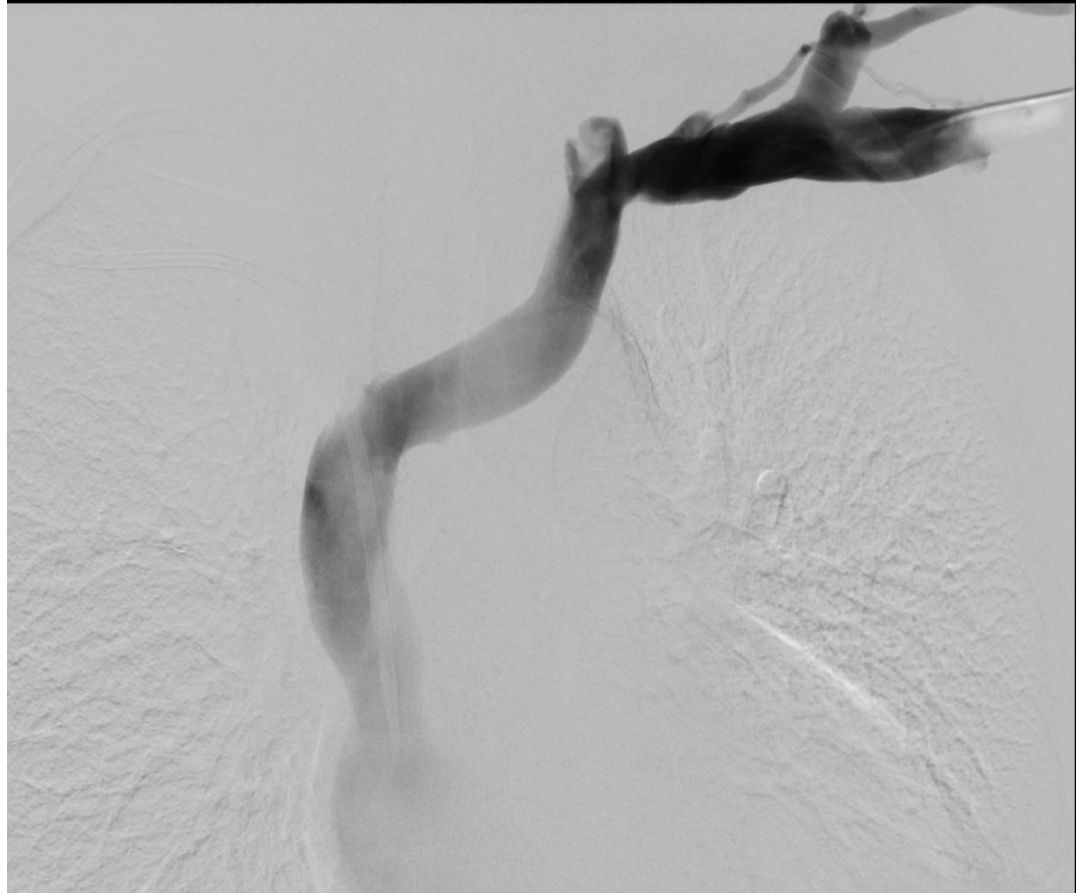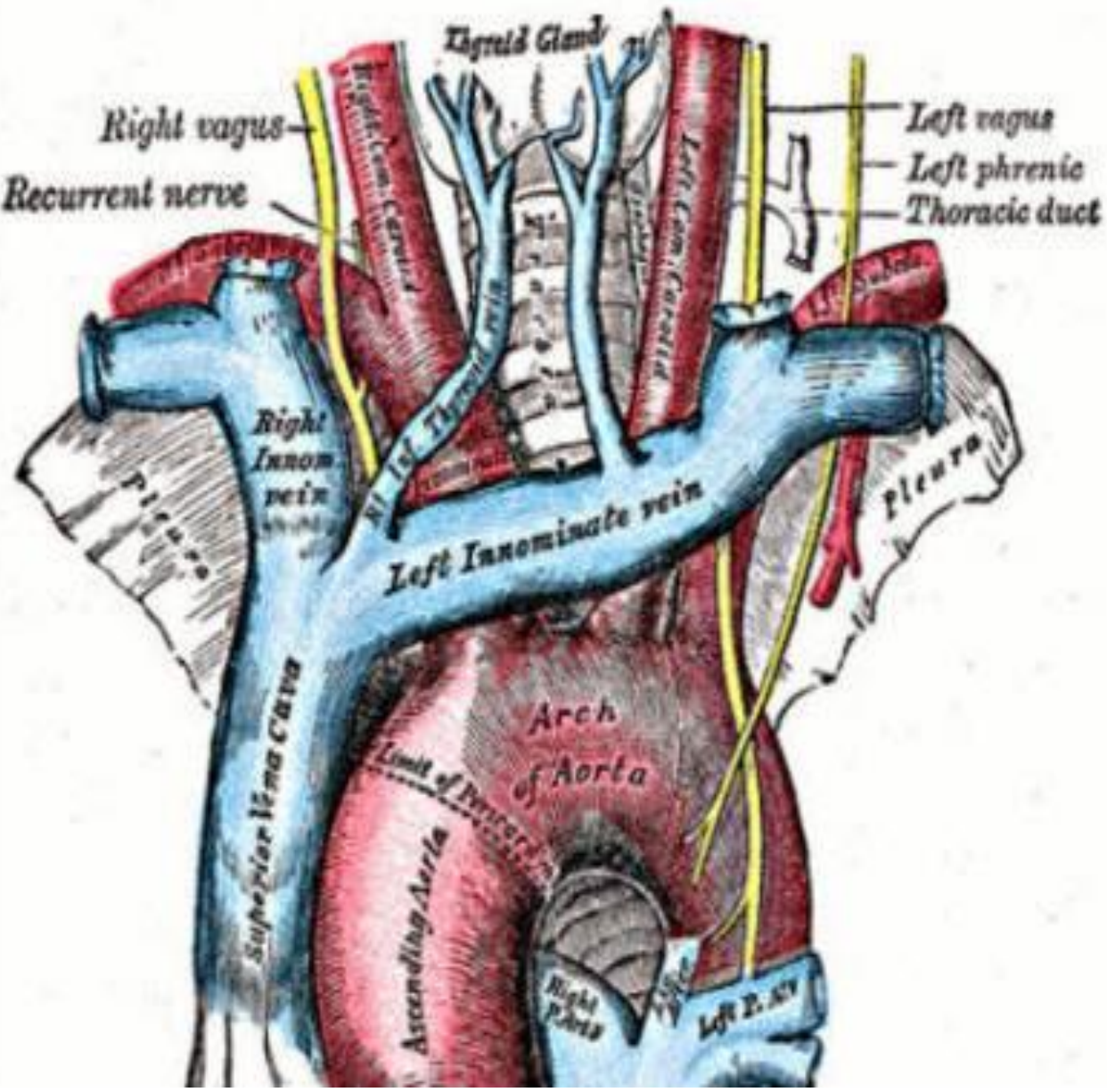


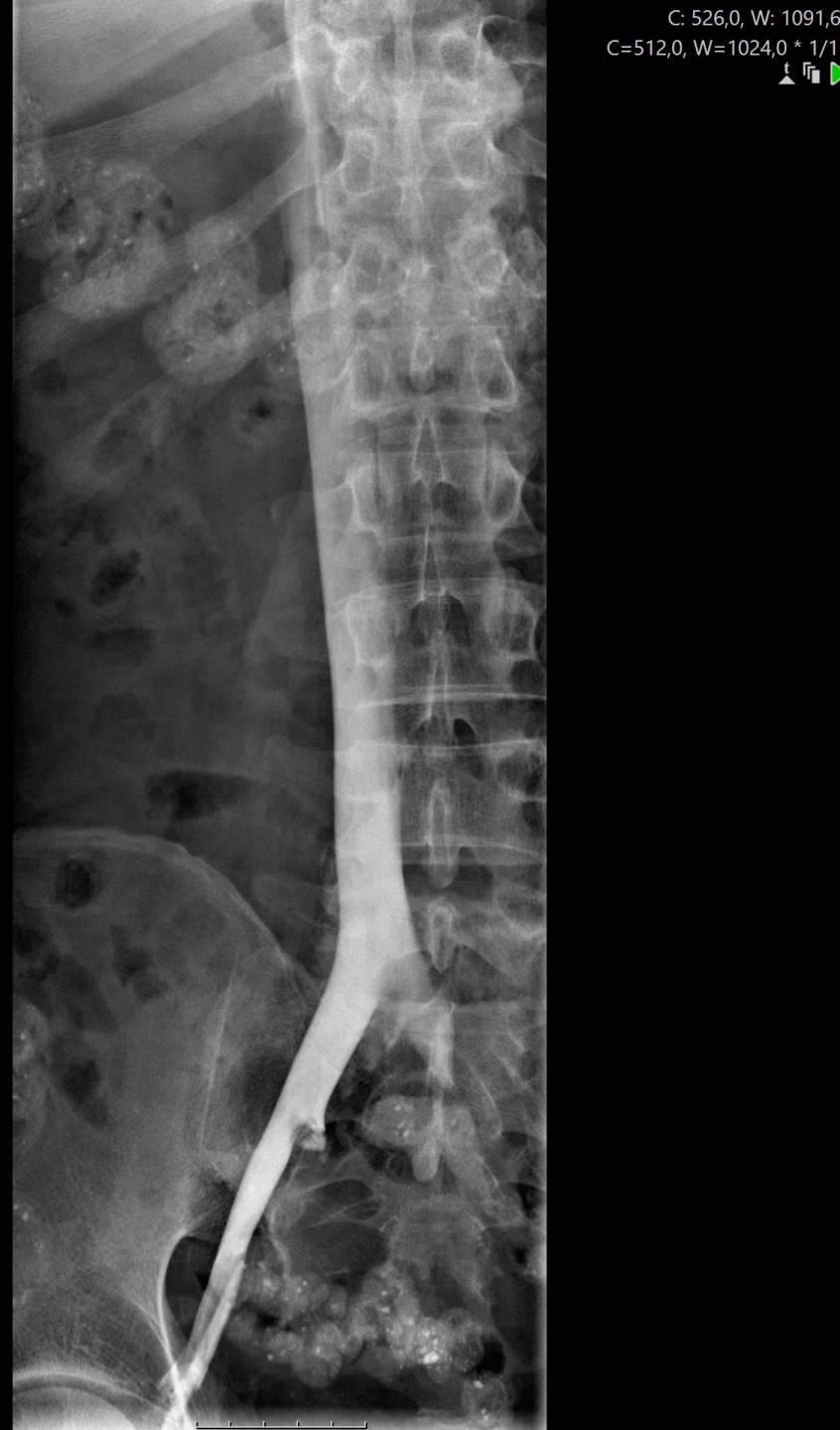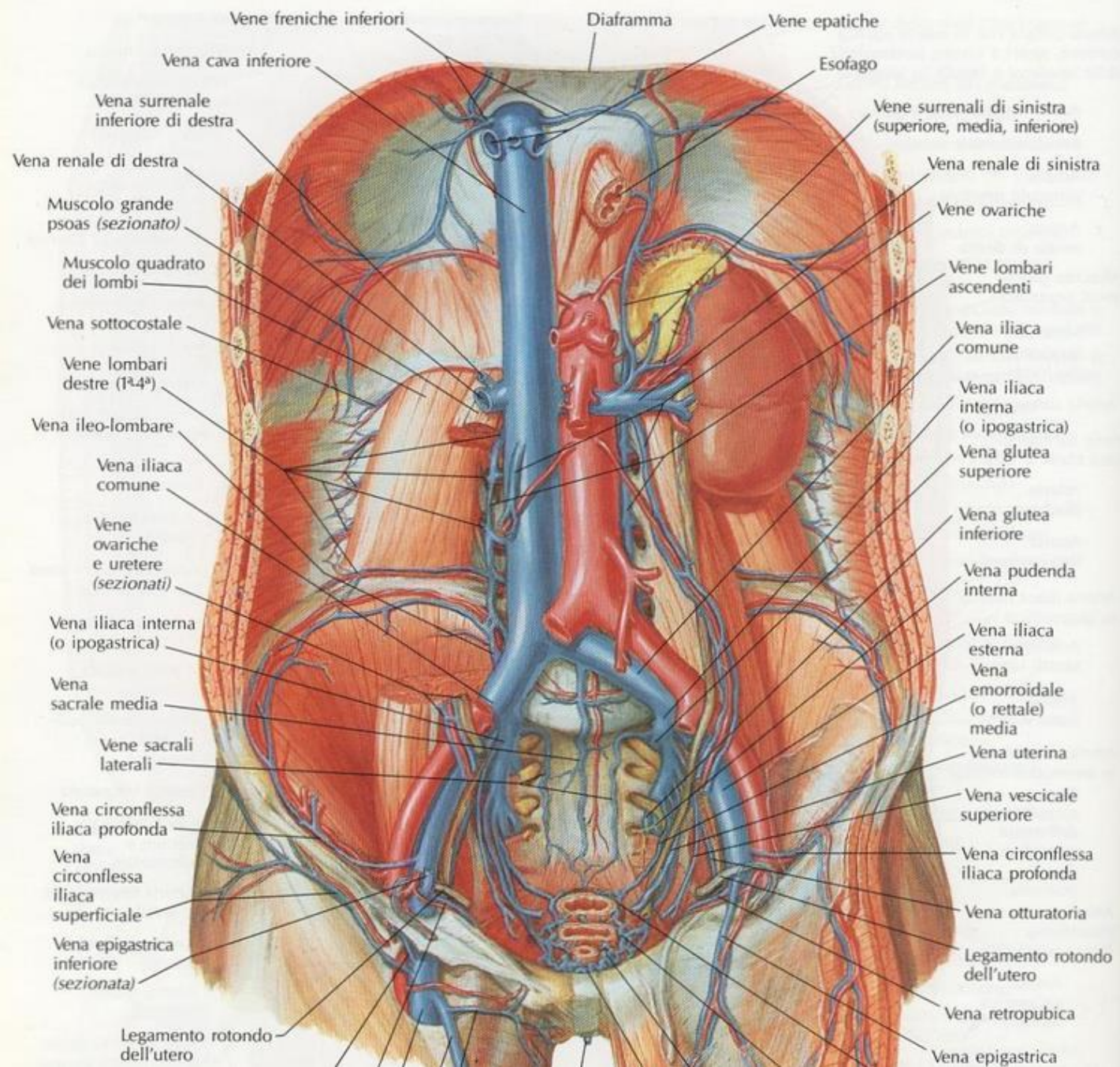
LA RADIOLOGIA INTERVENTISTICA NEL PAZIENTE DIALIZZATO

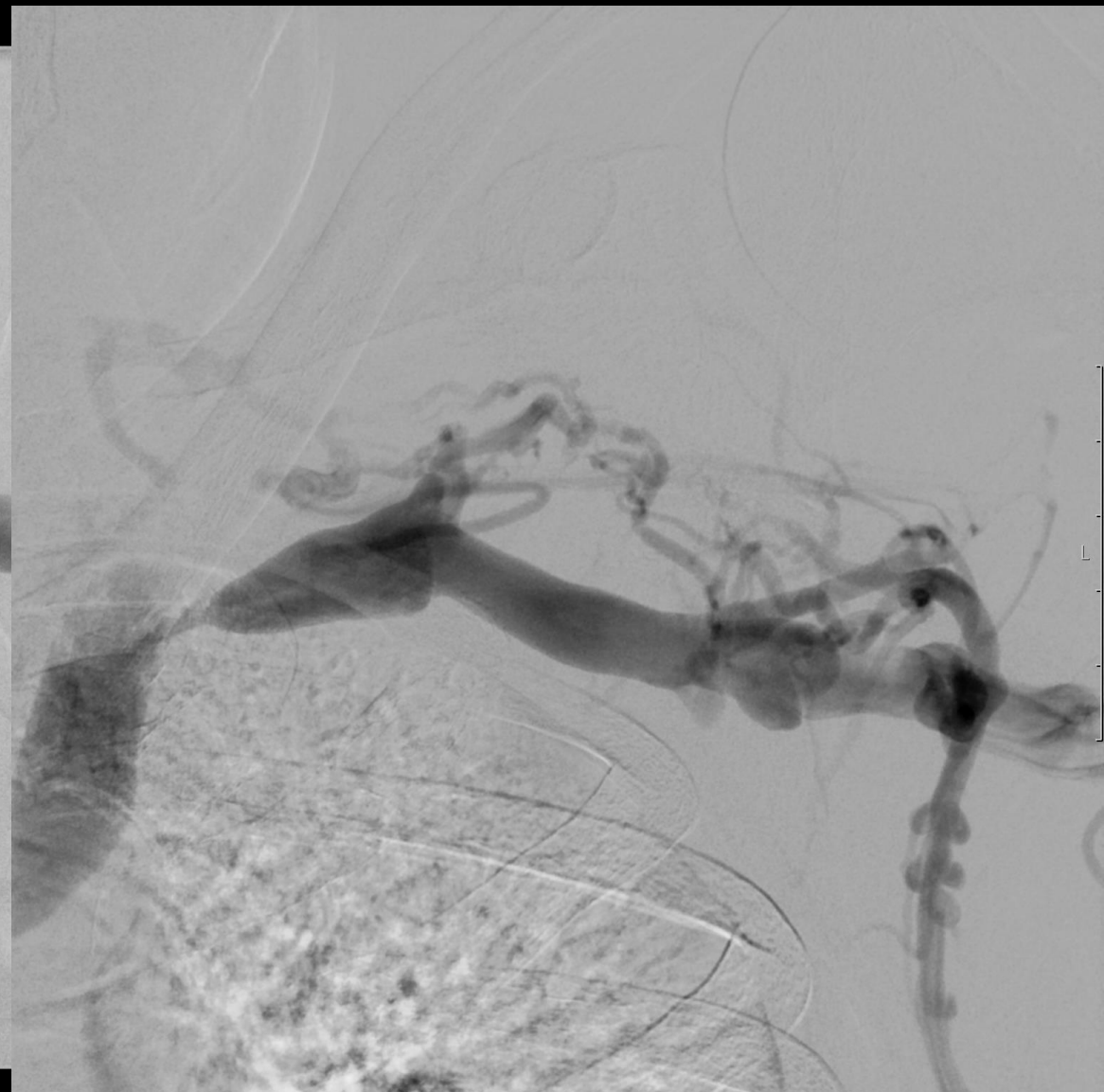
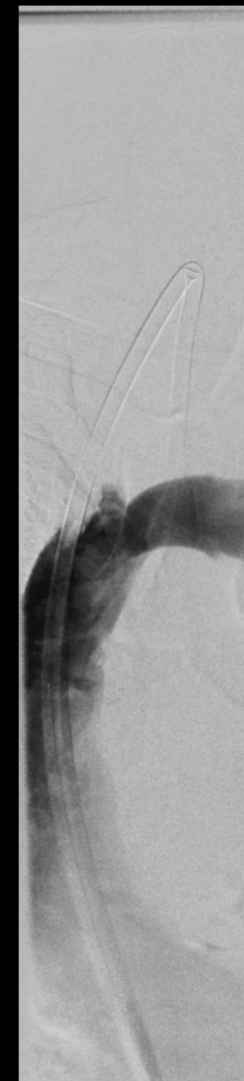
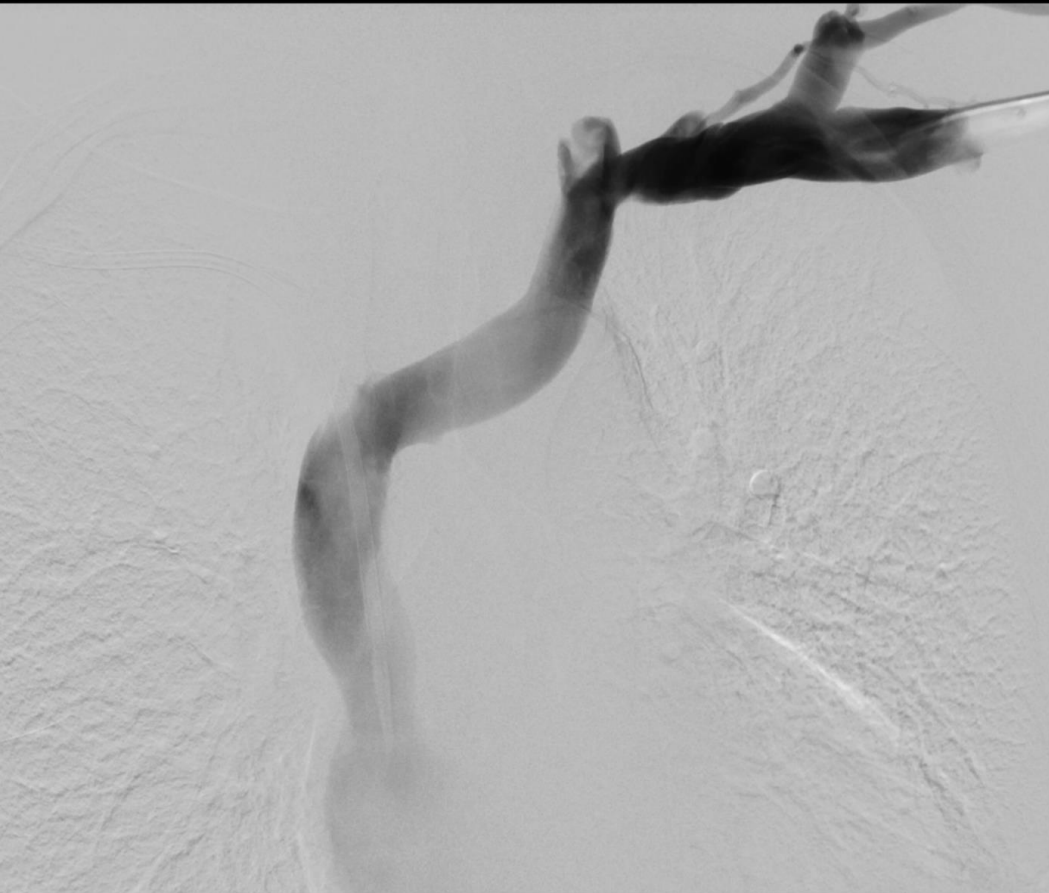

COSA VIENE CHIESTO AL RADIOLOGO INTERVENTISTA

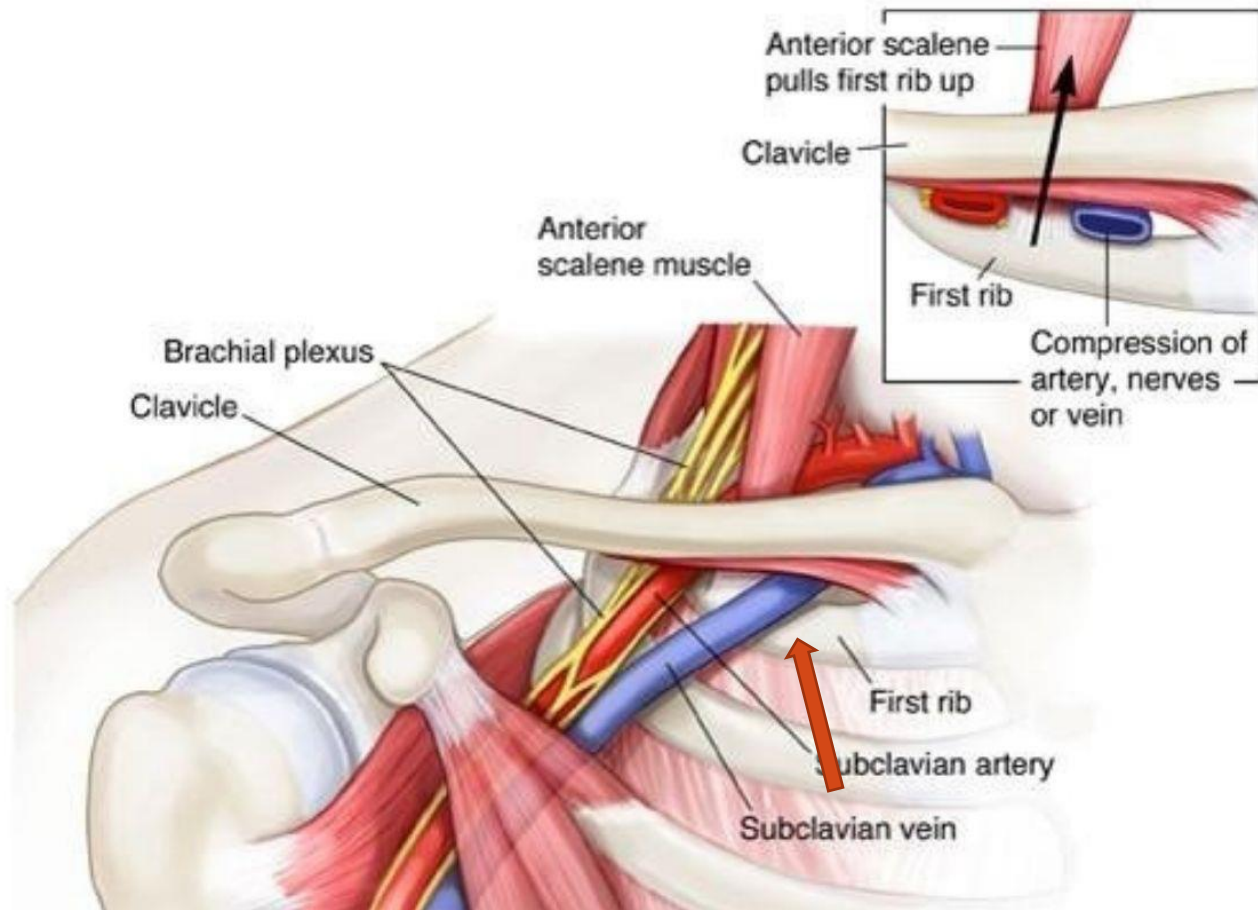
- **CERCARE LA CAUSA DEL MALFUNZIONAMENTO DI UNA FISTOLA / PROTESI**
 - **ECOGRAFIA**
 - **FLEBOGRAFIA DIAGNOSTICA**





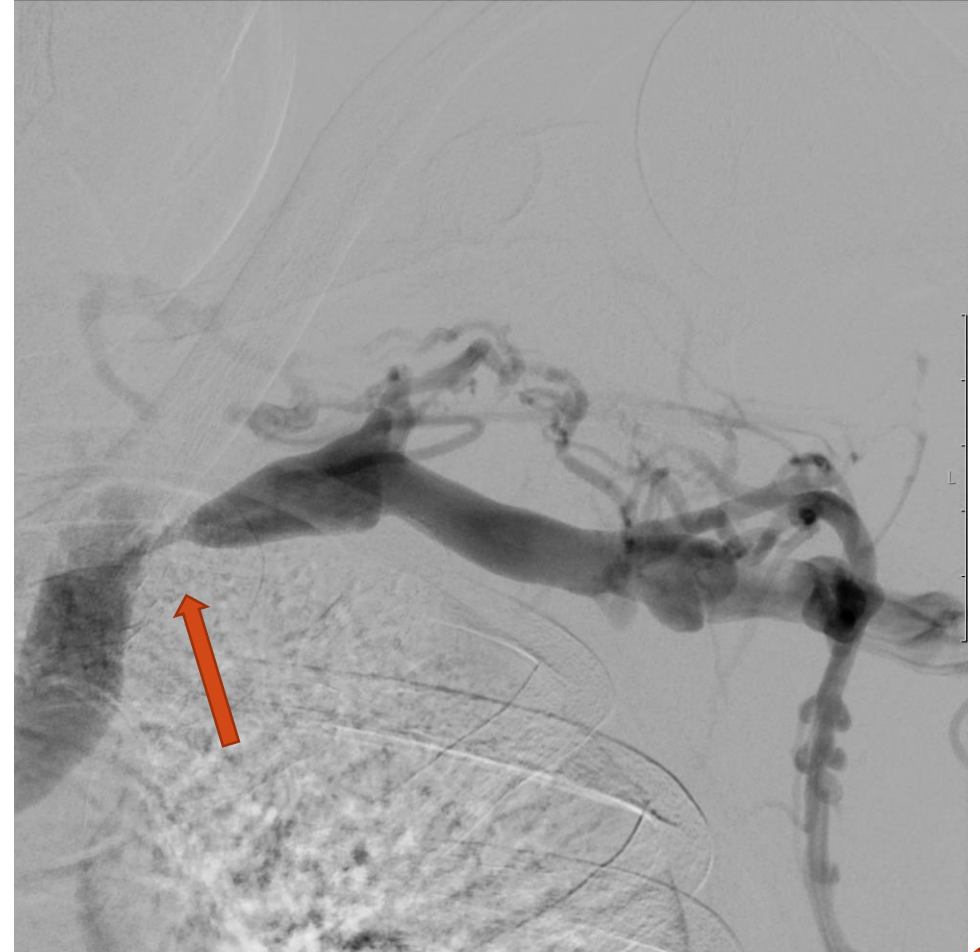


IN ALCUNI DISTRETTI ANATOMICI LA STENOSI È FAVORITA DALLE COMPRESSIONI OSSEE / VASCOLARI ESTRINSECHE



Età all'esame: 66 anni
Zoom pixel: 150%
5. Tace

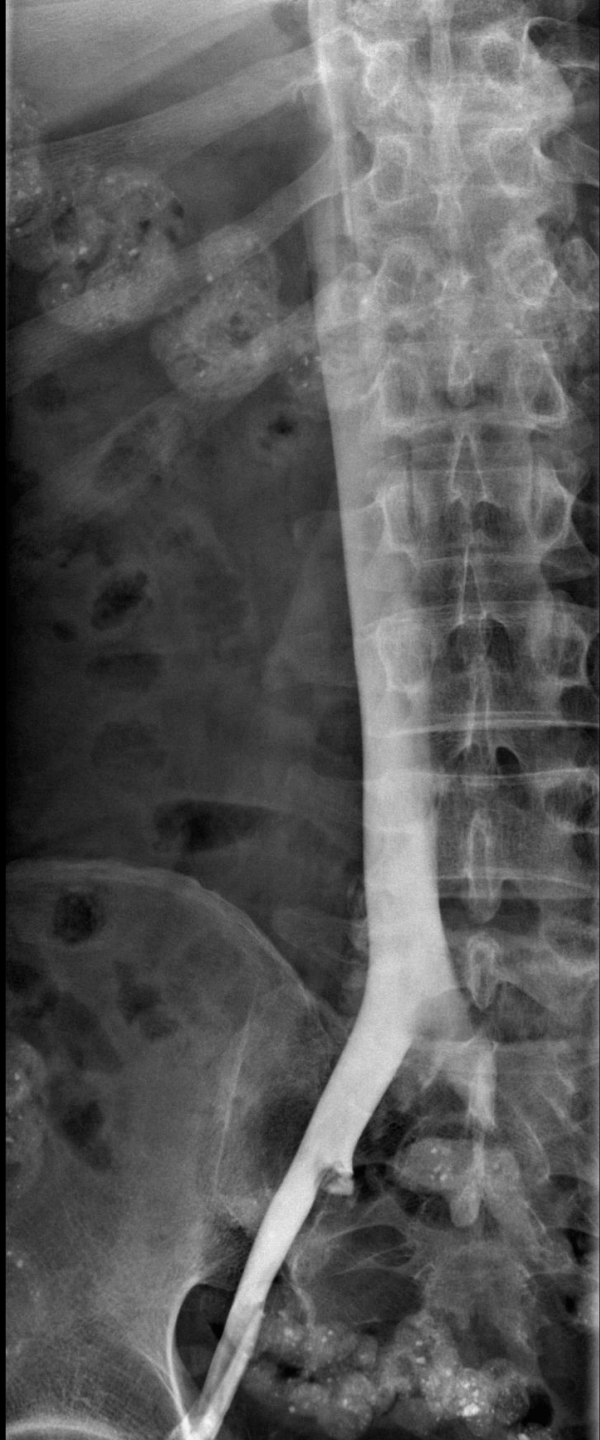C: 2464,0, W: 3553,1
C=2047,0, W=4095,0 * 1/1



- I flussi turbolenti ad alta gittata ed alta pressione sono la causa dell'iperplasia medio-intimale con conseguente stenosi venosa
- la presenza di un catetere venoso centrale (CVC) o degli elettrocateteri del PM condiziona spesso una reazione fibrotica della parete venosa



Età all'esame: 67 anni
Zoom pixel: 67%
1.00/00 ▾



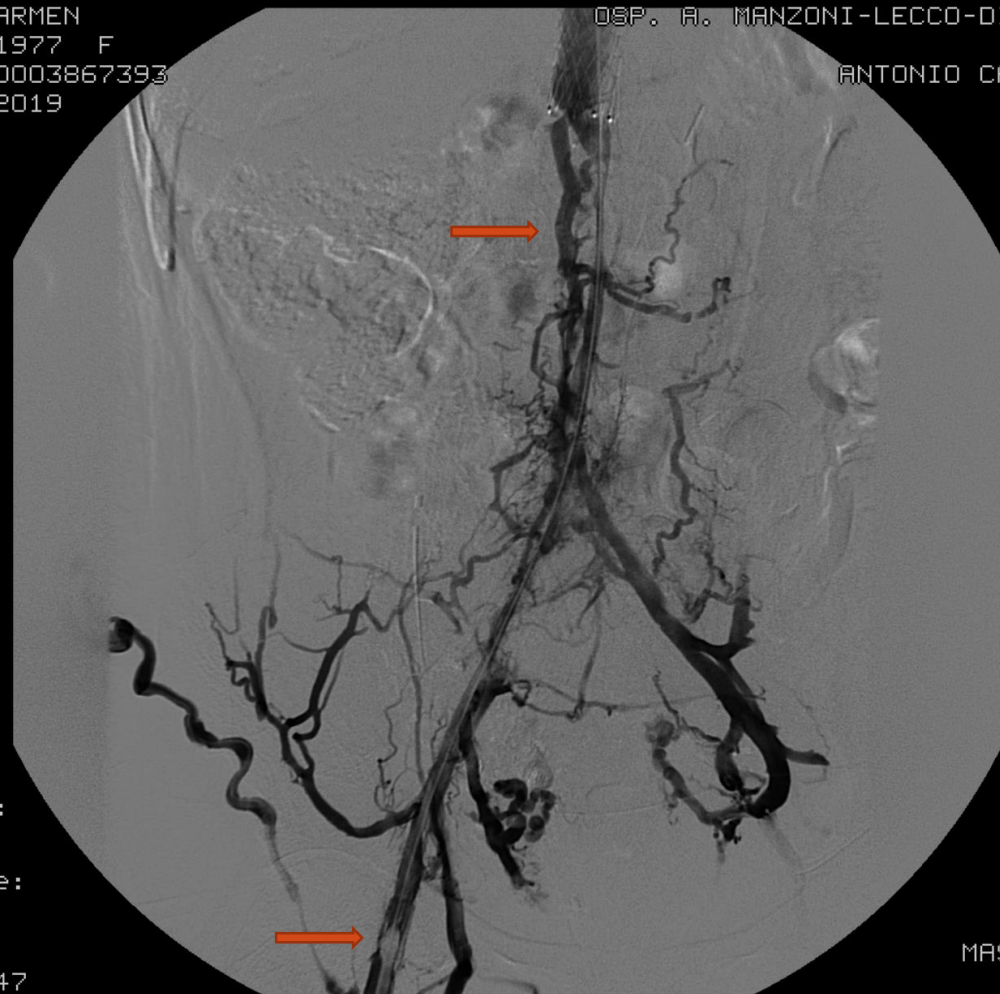
C: 526,0, W: 1091,6
C=512,0, W=1024,0 * 1/1
▲ ▢ ▣ ▤

Età all'esame:
Zoom pixel: 120%
1. ▾

NASO, CARMEN
17-06-1977 F
CNU@000003867393
18-06-2019

OSP. A. MANZONI-LECCO-DIP. RAD.

ANTONIO CAPPELLO



T-mask:
0.52
T-image:
3.12
T-run:
11:46:47

ROT
0

ANG
1

RUN
3

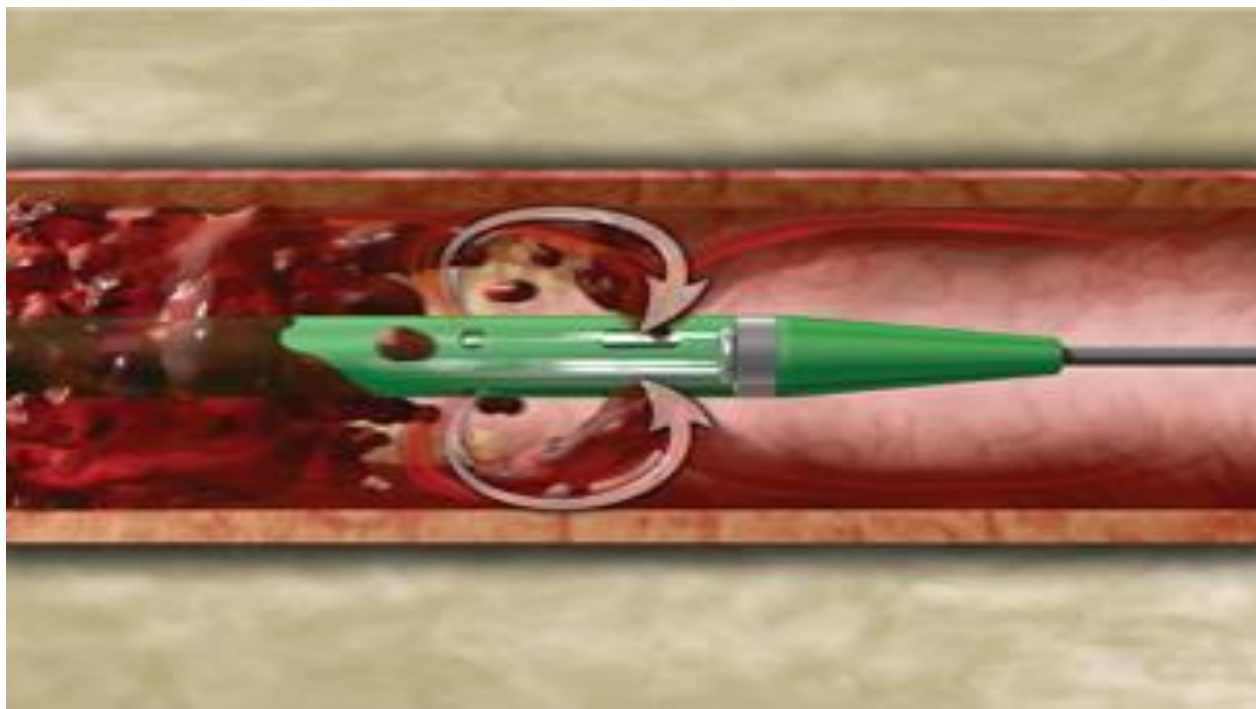
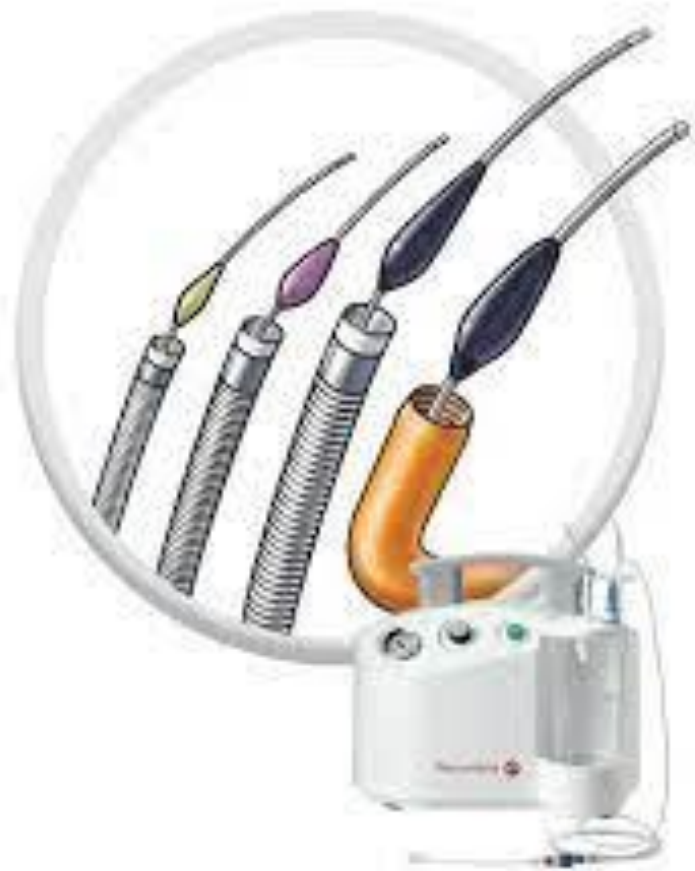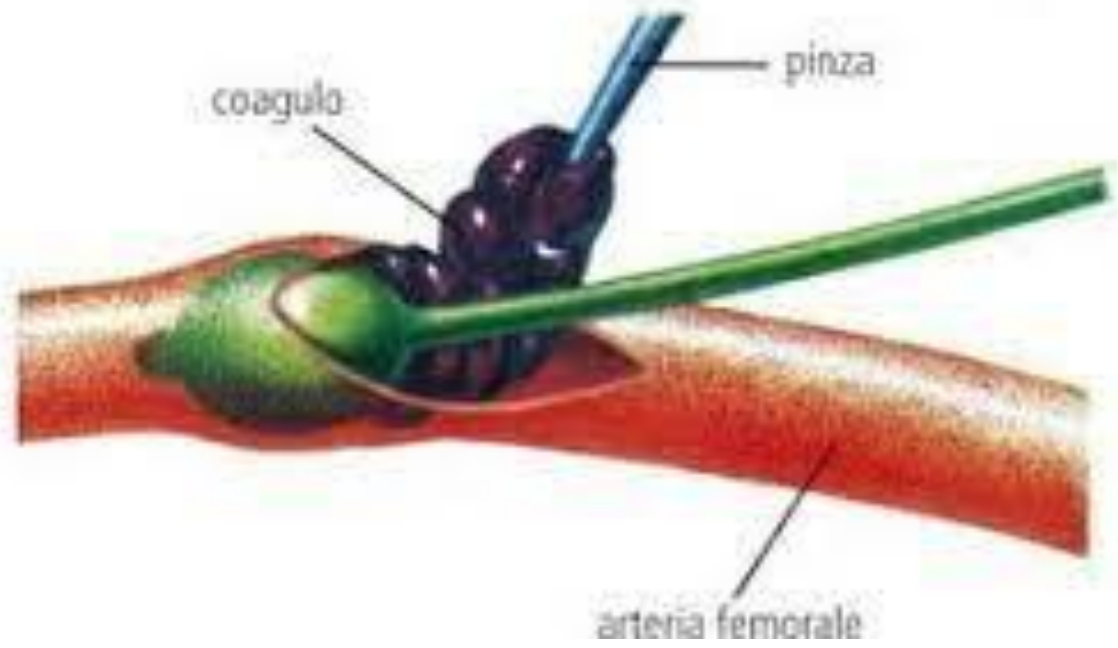
21

MASK IMAGE
2 7

ATTIVITA' DEL RADIOLOGO INTERVENTISTA

- **Trombolisi / tromboaspirazione
(meccanica / farmaco-meccanica)**
- **PTA**
- **STENTING**

C



PTA (ANGIOPLASTICA PERCUTANEA)

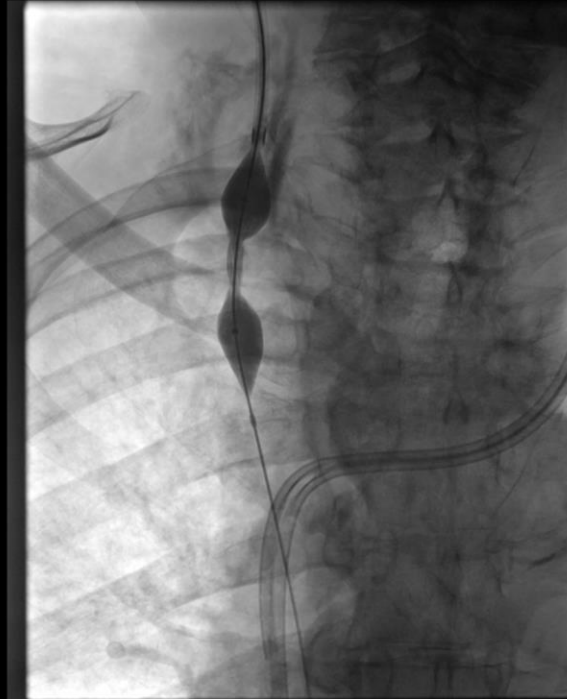
Età all'esame: 77 anni

Zoom pixel: 150%

13. Single ▾

C: 2047,0, W: 4095,0

C=2047,0, W=4095,0 1/1



06/05/2021, 15:21:16

F

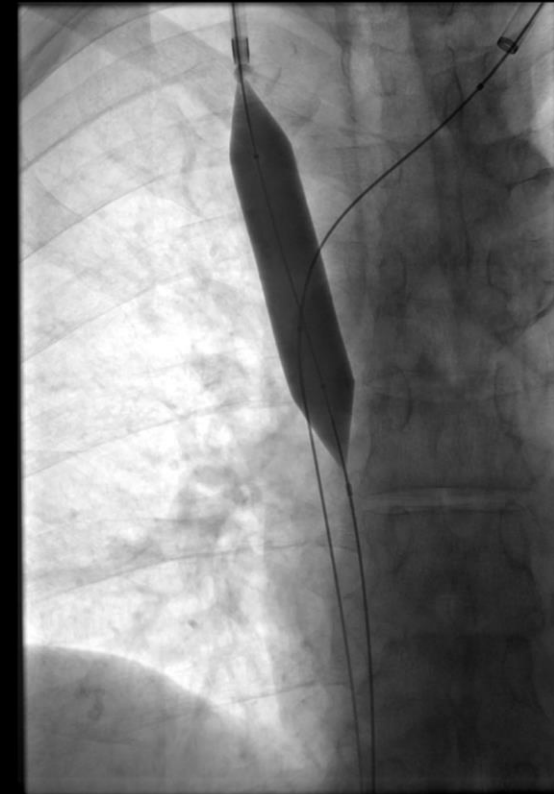
Età all'esame: 62 anni

Zoom pixel: 150%

14. Single ▾

C: 2047,0, W: 4095,0

C=2047,0, W=4095,0 1/1



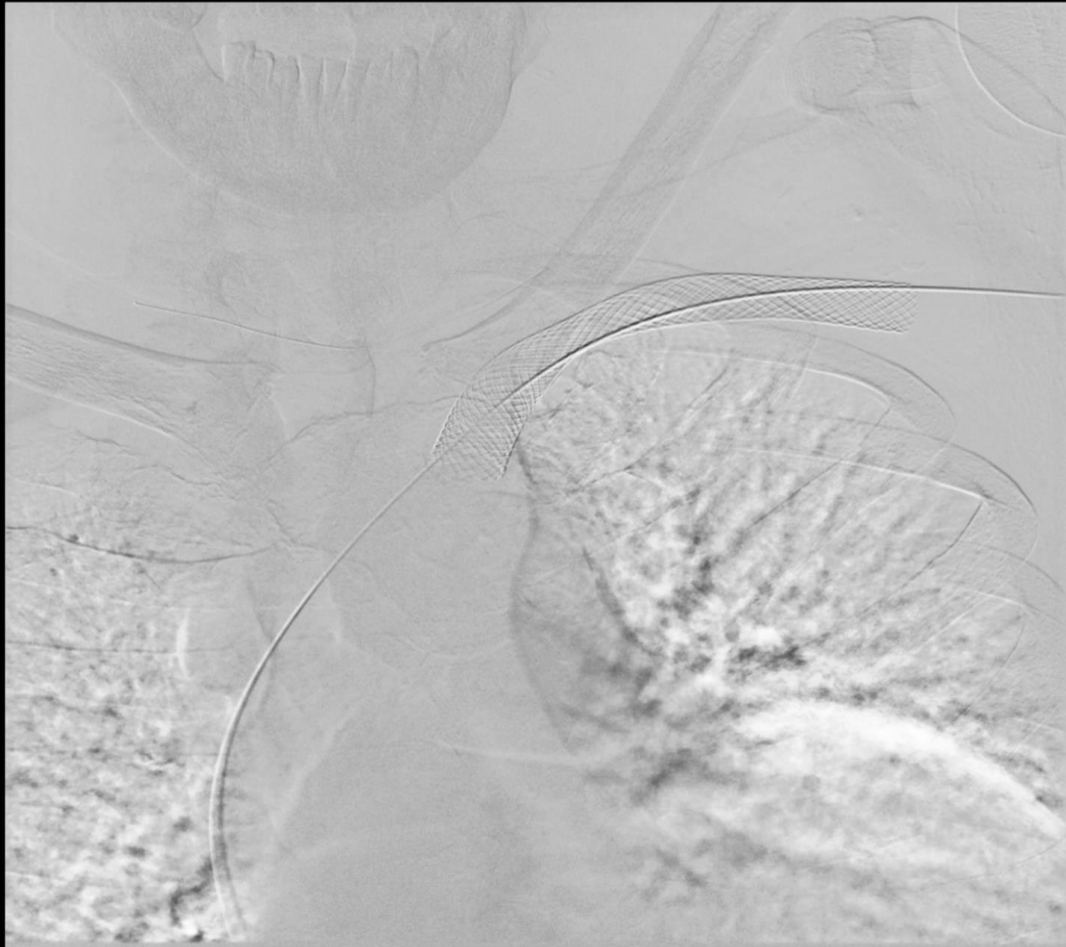
11/12/2020, 12:53:52

F

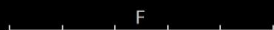STENTING

Età all'esame: 66 anni
Zoom pixel: 150%
13. Tace ▾

C: 2047,0, W: 4095,0
C=2047,0, W=4095,0 1/1
▲ ▢ ▶

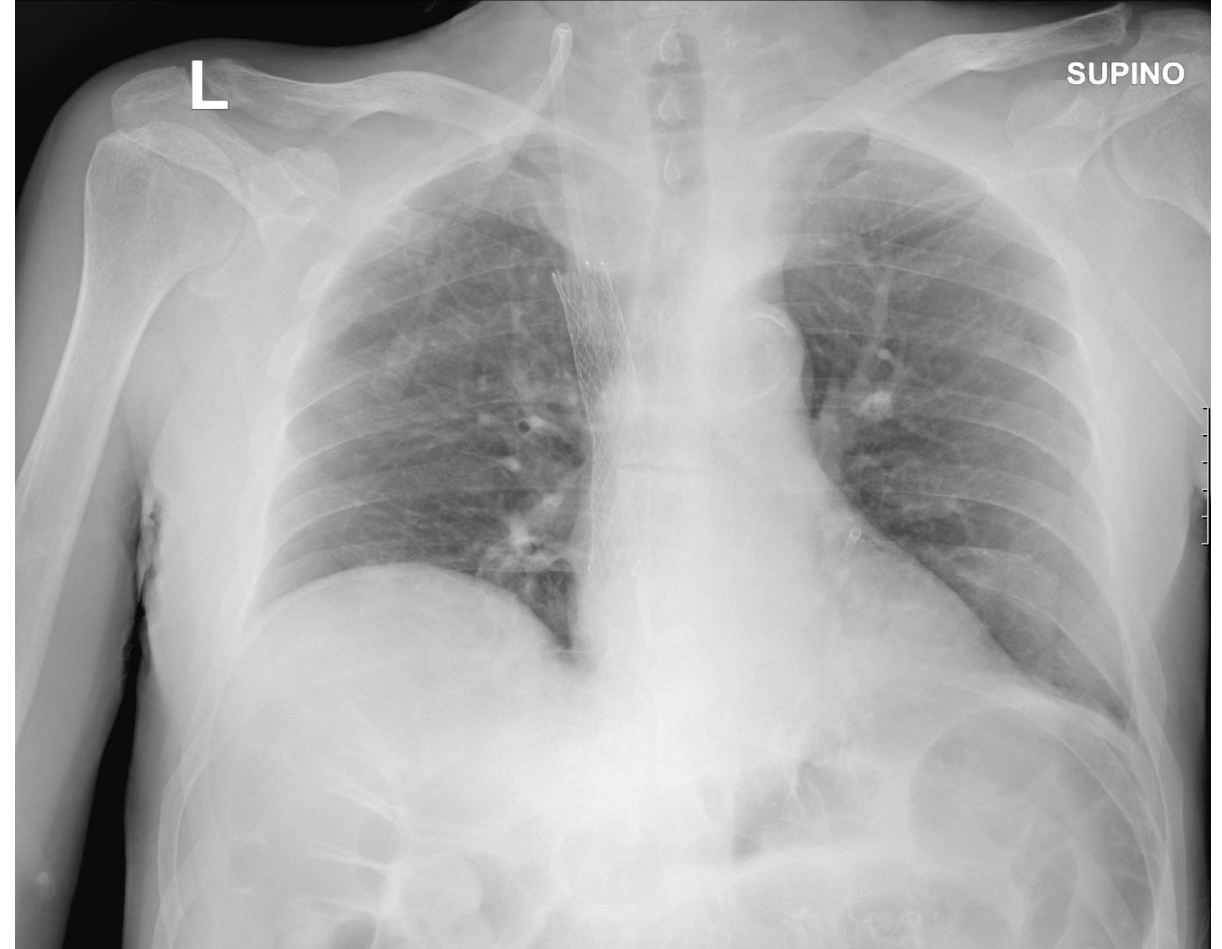


05/08/2021, 11:56:00



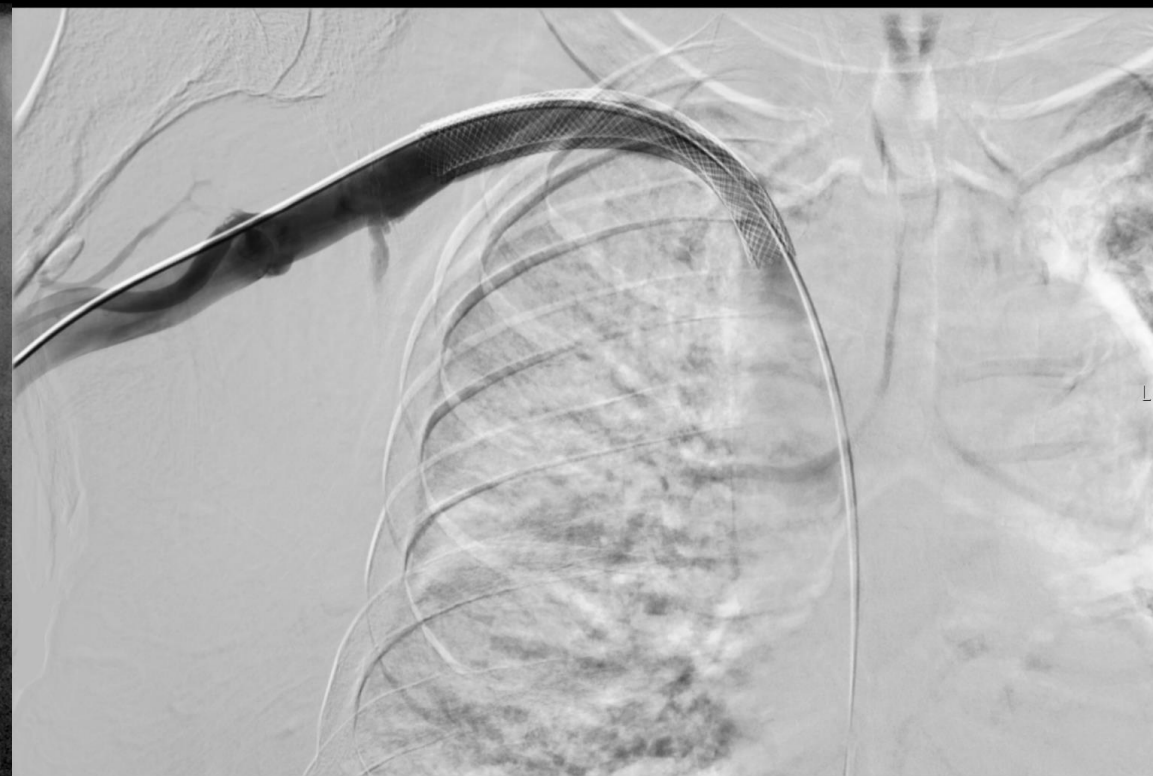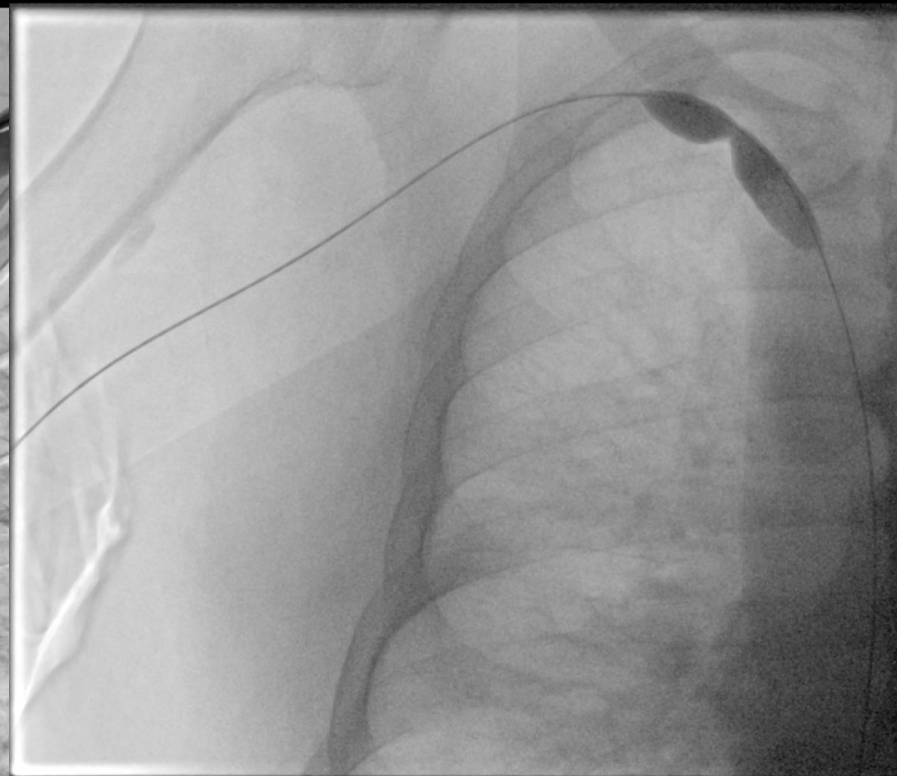
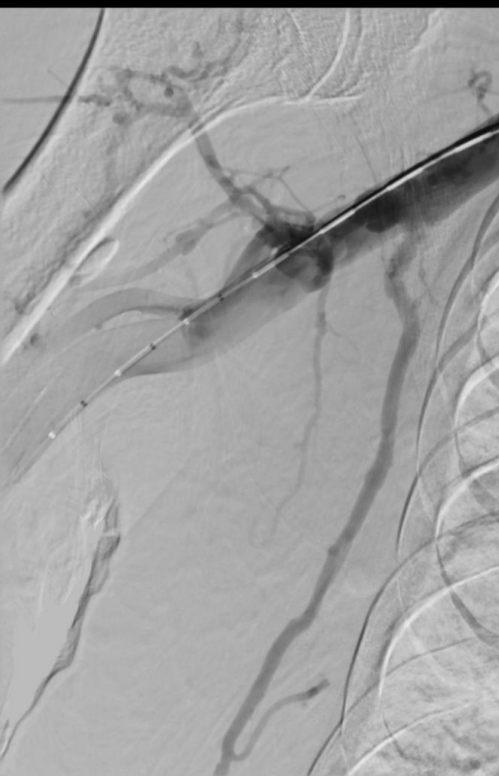
Età all'esame: 63 anni
Zoom pixel: 54%
1. X Torace a letto ▾

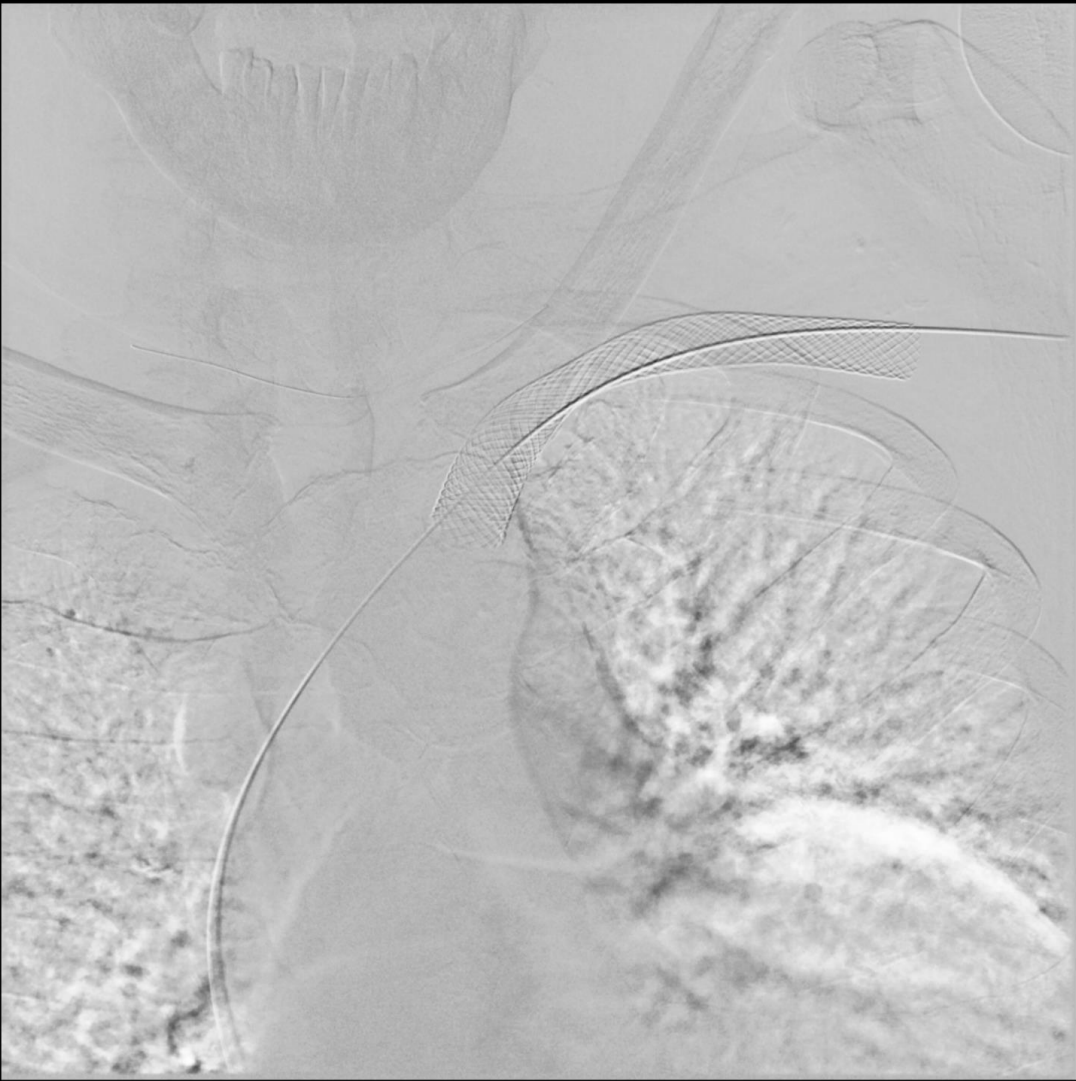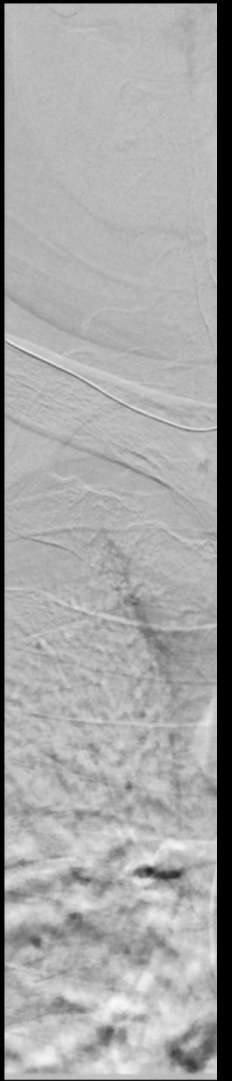
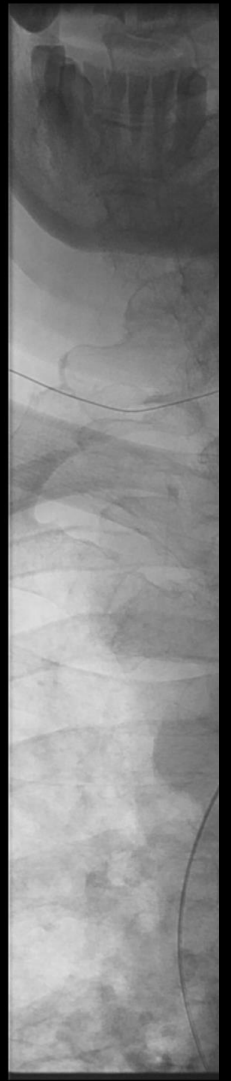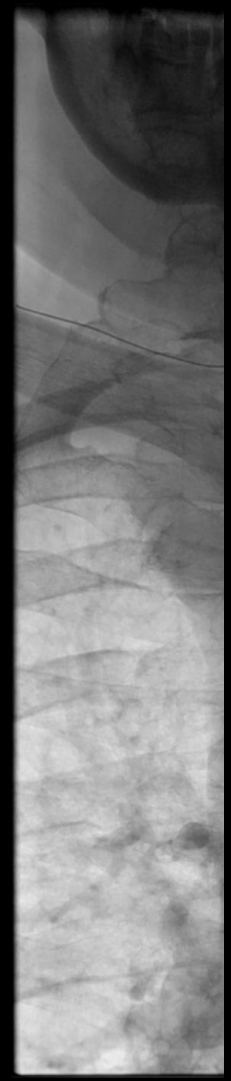
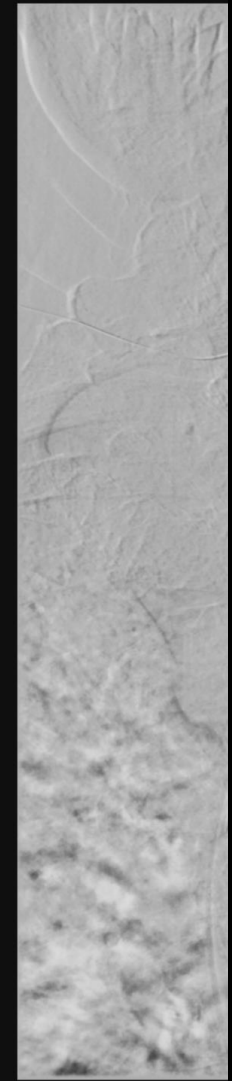
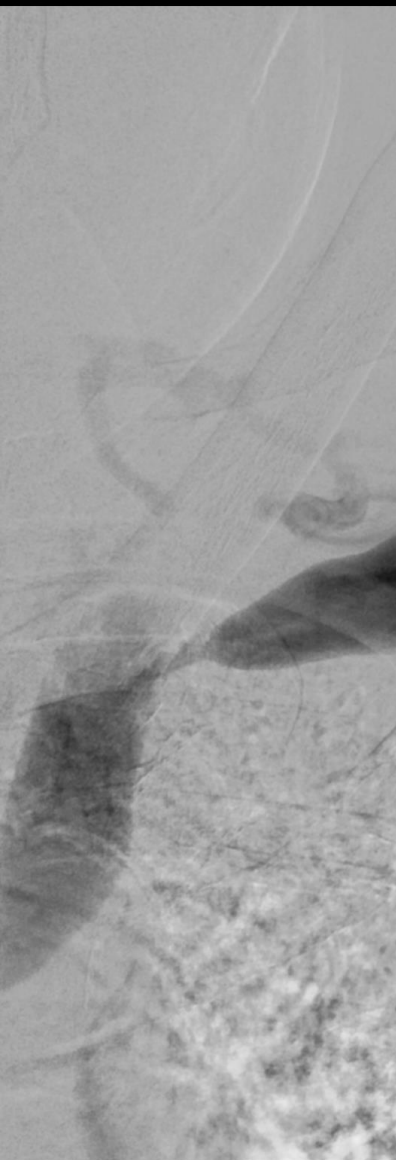
C: 22128,0, W: 48672,0
C=22128,0, W=48672,0 1/3
S: 0
▶

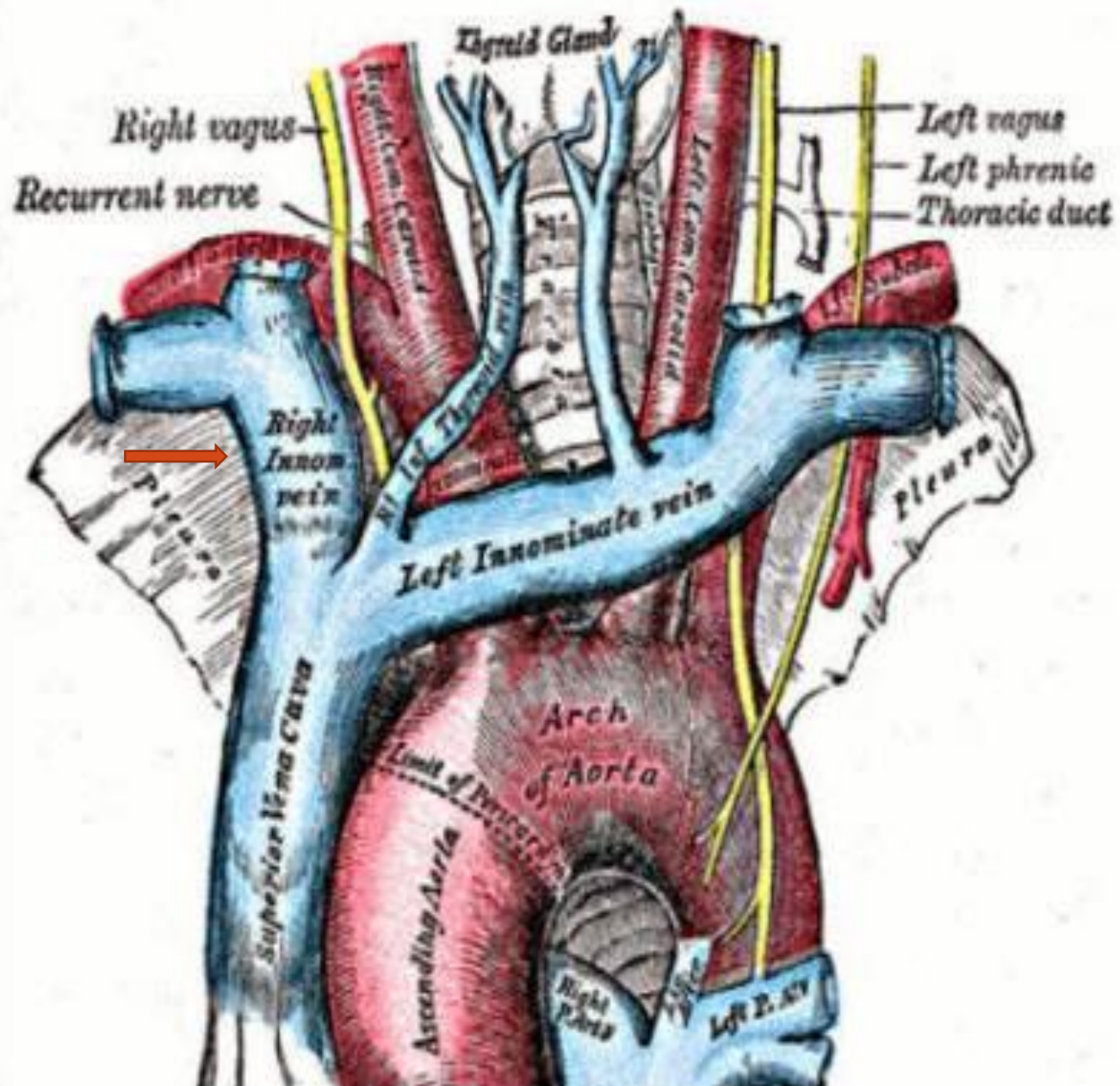


467
28/05/2021, 17:24:41



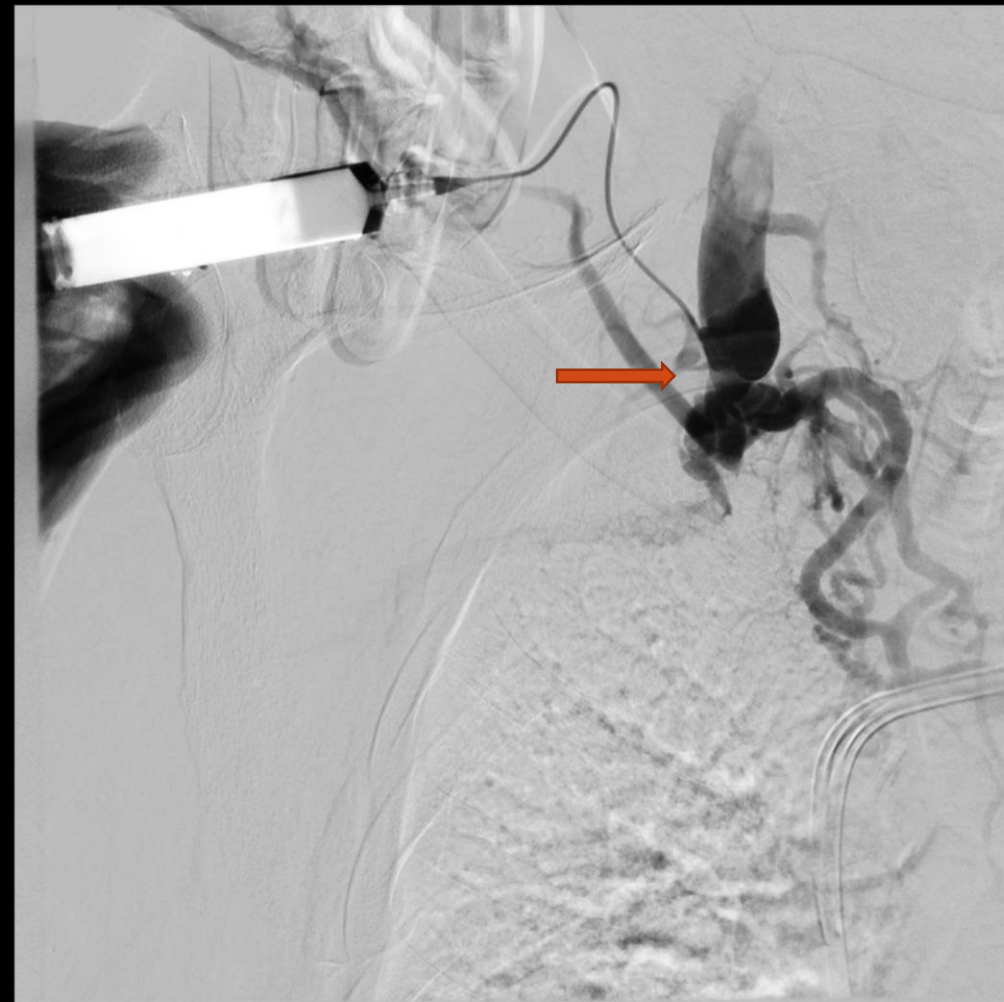





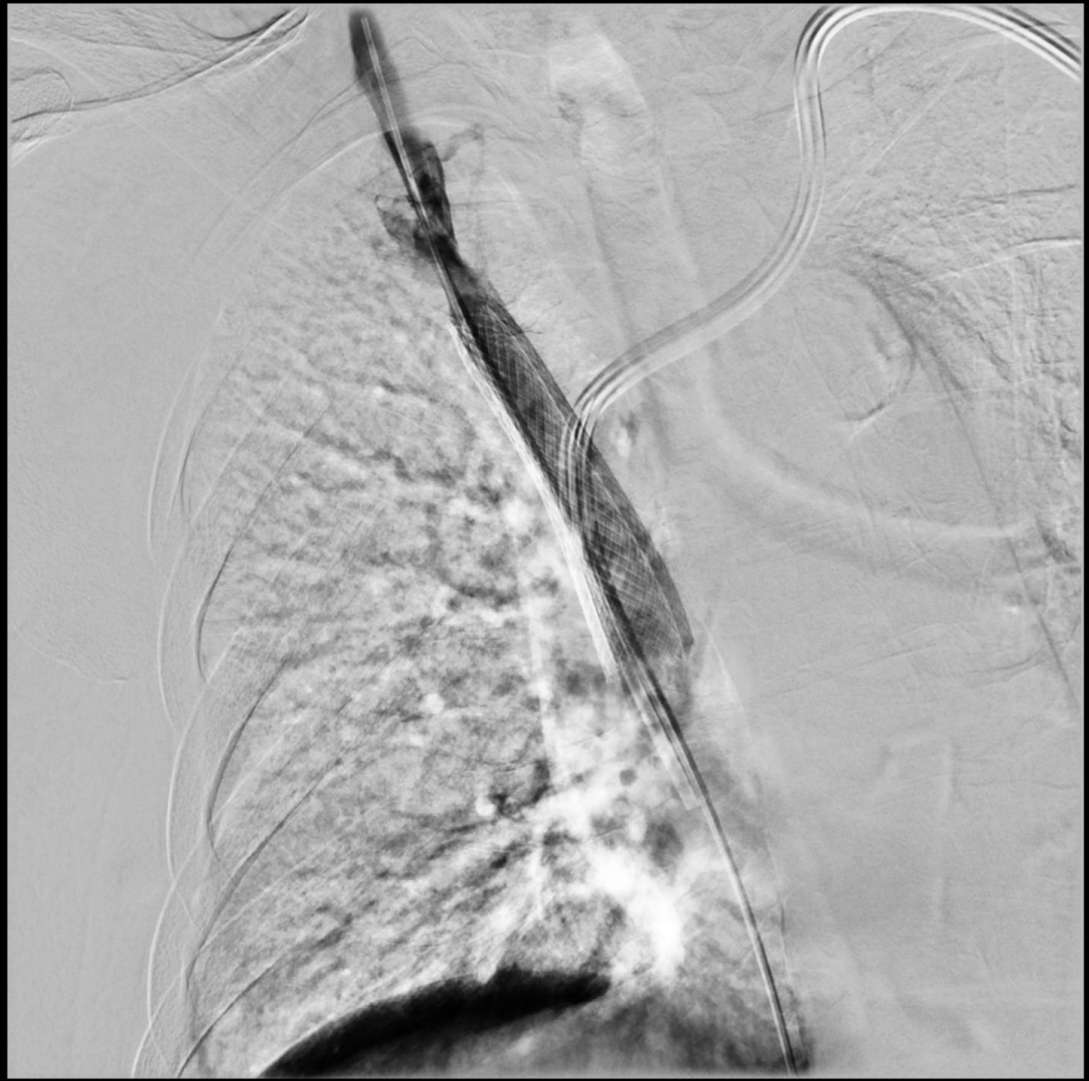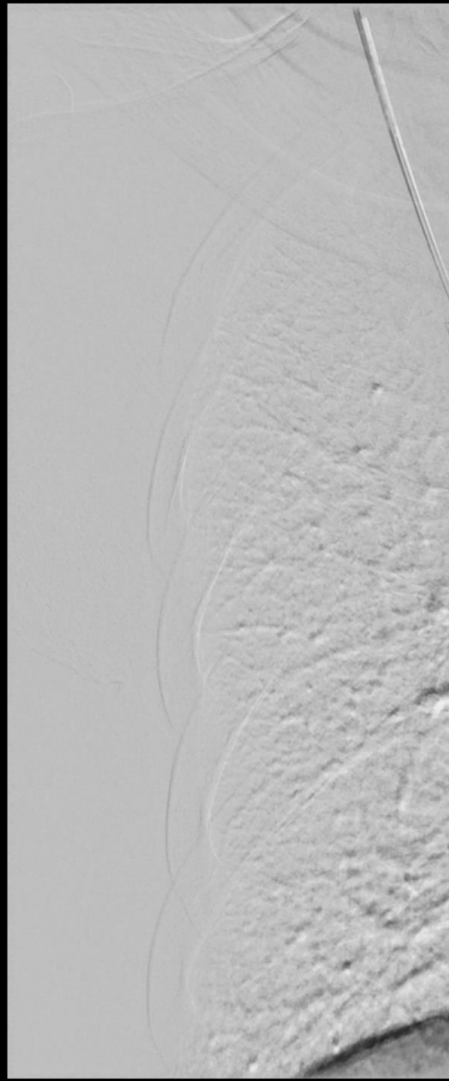
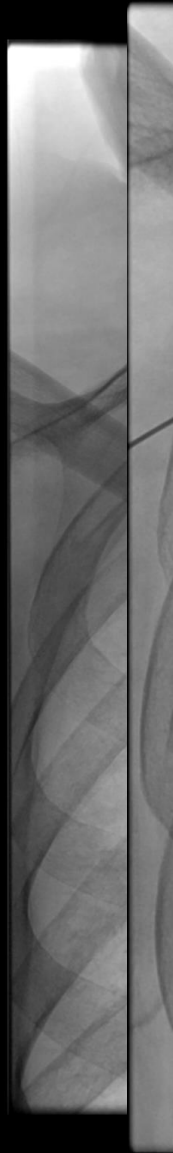
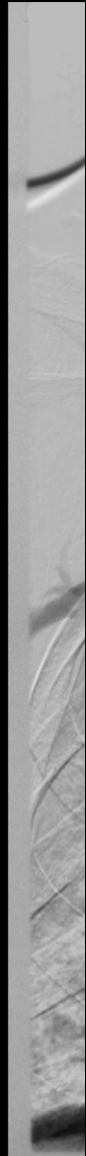
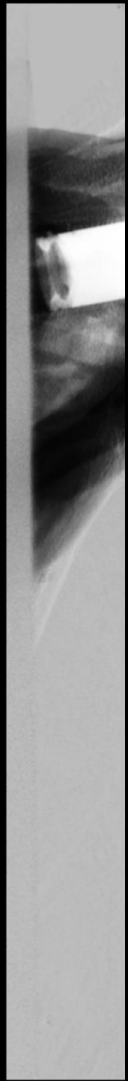
Età all'esame: 77 anni
Zoom pixel: 150%
2. Addome 2 ▾

C: 2047,0, W: 4095,0
C=2047,0, W=4095,0 1/1



06/05/2021, 14:27:44

F



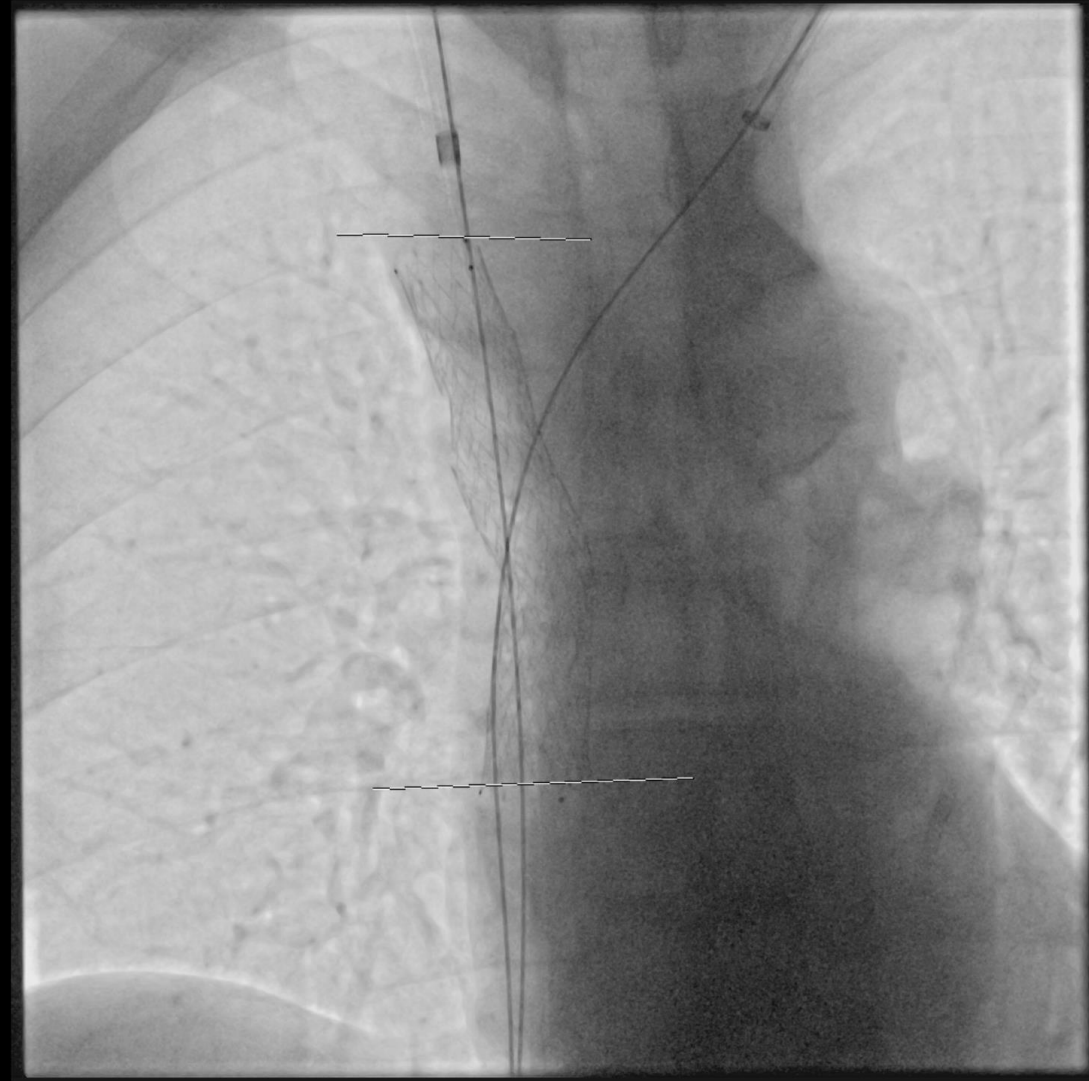
Età all'esame Età all'esame Età all'esame: 62 an Età all'esame: 62 anni
Zoom pixel: 1 REF Zoom pixel: 150% Zoom pixel: 150%
1. Torace DS/ Zoom pixel: 1 3. Torace DSA 2 ▾ 7. Torace DSA 2 ▾
2. Torace DS/

Età all'esar Età all'esame: 62 anni
Zoom pixe Zoom pixel: 150%
8. Torace I 14. Single ▾

Età all'esame: Età all'esame: 62 anni
Zoom pixel: 1 Zoom pixel: 150%
10. Single ▾ 19. Single ▾

Età all'esame: 62 anni
Zoom pixel: 150%
23. FL Torace sharp ▾

C: 2047,0, W: 4095,0
C=2047,0, W=4095,0 1/1
🔍 📄 🏠



Età all'esame: 62 anni
Zoom pixel: 150%
24. Torace DSA 2 ▾

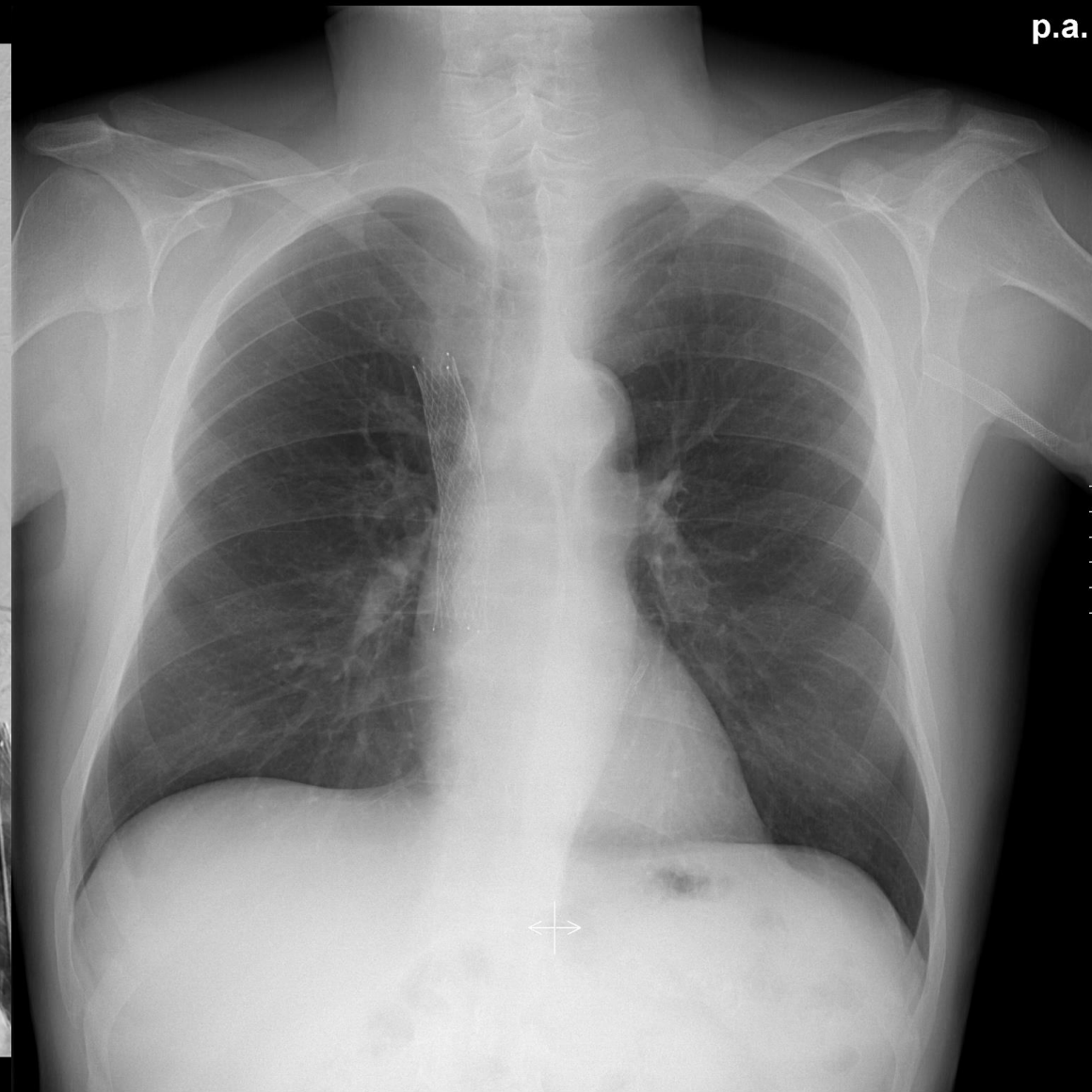
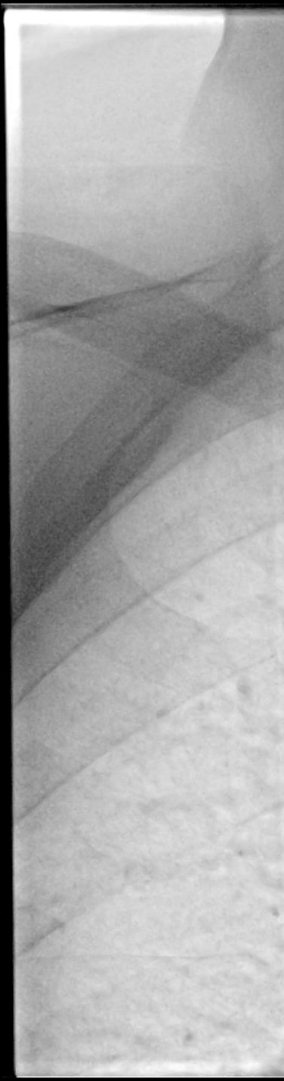

Età all'esame: 62 anni
Zoom pixel: 150%
24. Torace DSA 2 ▾

Età all'esame: 62 anni
Zoom pixel: 150%
28. FL Torace sharp ▾

Età all'esame: 62 anni
Zoom pixel: 150%
30. Torace DSA 2 ▾

Età all'esame: 63 anni
Zoom pixel: 51%
1. TORACE ▾

C: 1958,0, W: 2632,0
C=1958,0, W=2632,0 1/3
S: 400



p.a.

11/12/2020, 13:47:42

11/12/2020, 13:47:42

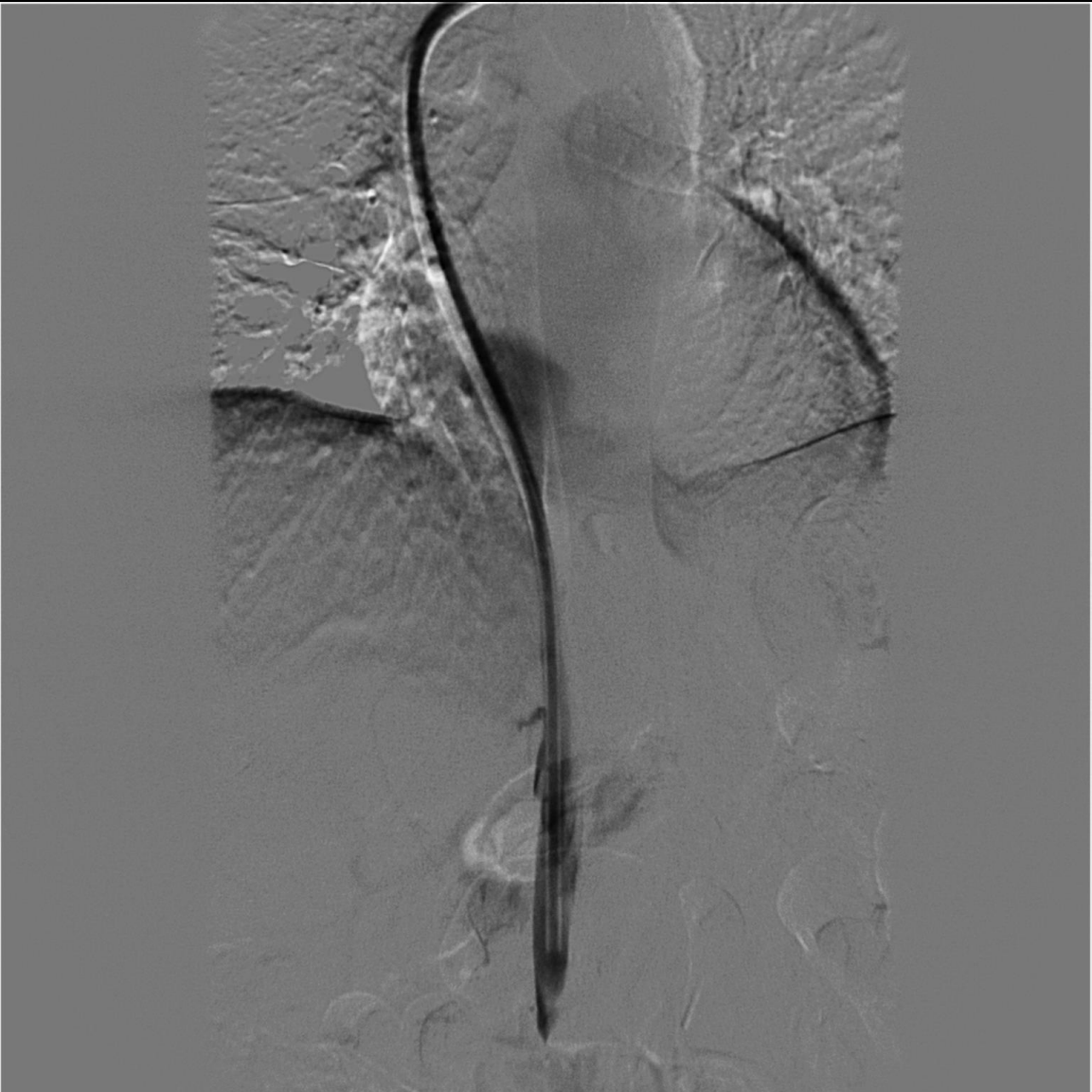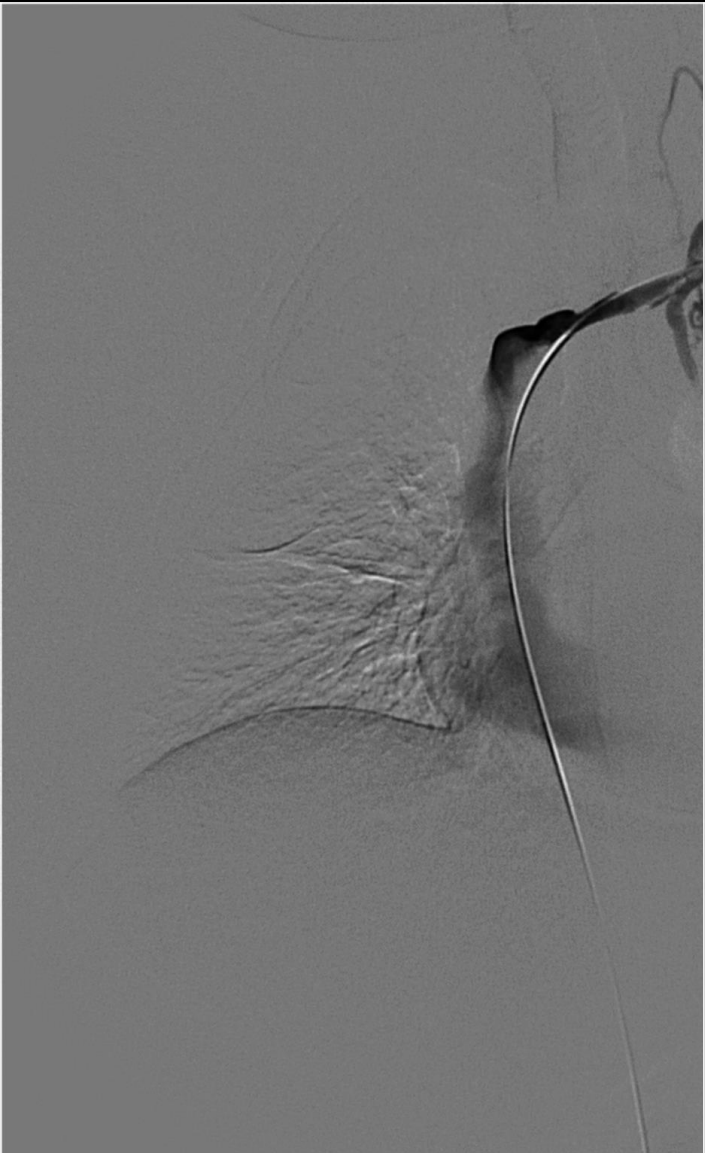
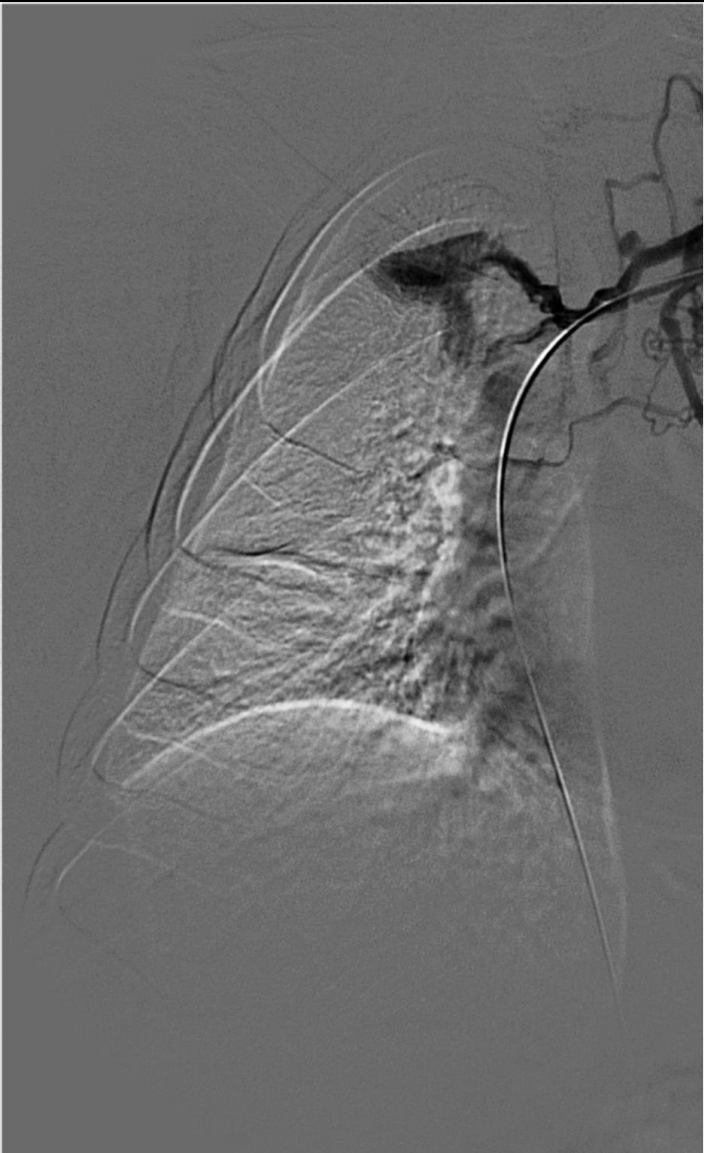11/12/2020, 13:55:26

11/12/2020, 14:26:13

19/05/2021, 10:05:15

IL MANTENIMENTO DELL'ACCESSO DIALITICO È SPESSO FRUSTRANTE





Età all'esame Età all'esame Età all'esame:
Zoom pixel: Zoom pixel: Zoom pixel: 120%
1. v 1. v 1. v

Età all'esame:
Zoom pixel: 120%
1. v

Età all'esame:
Zoom pixel: 120%
1. v

Età all'esame:
Zoom pixel: 150%
18. v

Età all'esame:
Zoom pixel: 120%
1. v

C: 127,5, W: 255,0
C=127,5, W=255,0 1/1
#

NASO, CAFNASO, CAF
17-06-1917-06-19
CNU@0000CNU@0000
29-08-2017-08-2017

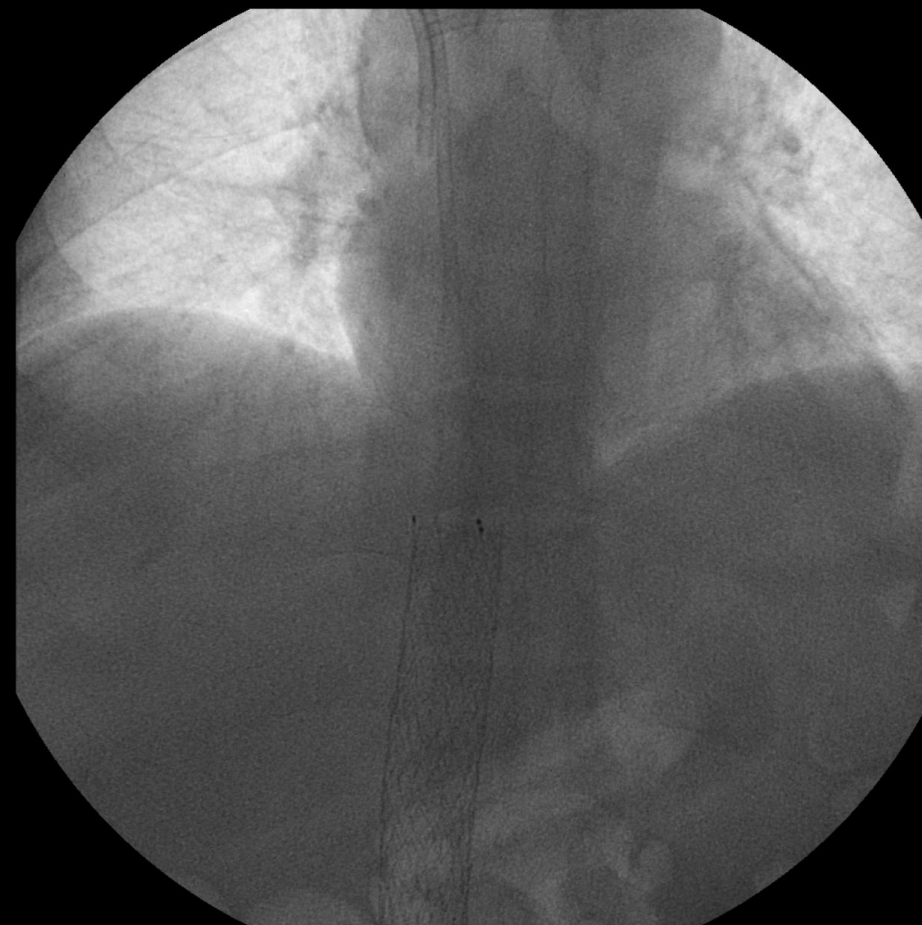
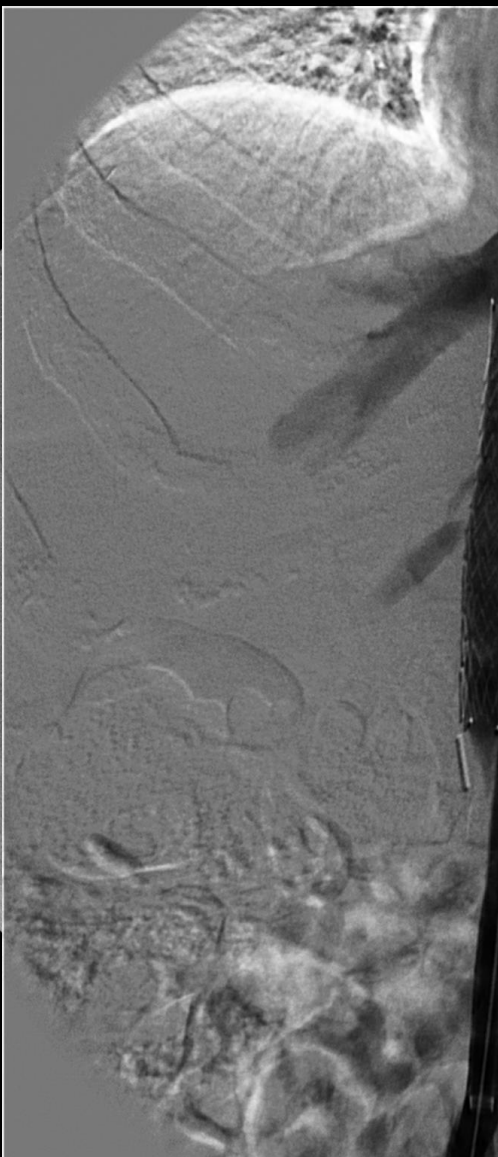
NASO, CARMEN
17-06-1977 F 17-06-1977
CNU@000000386739;CNU@000000386
29-08-2017

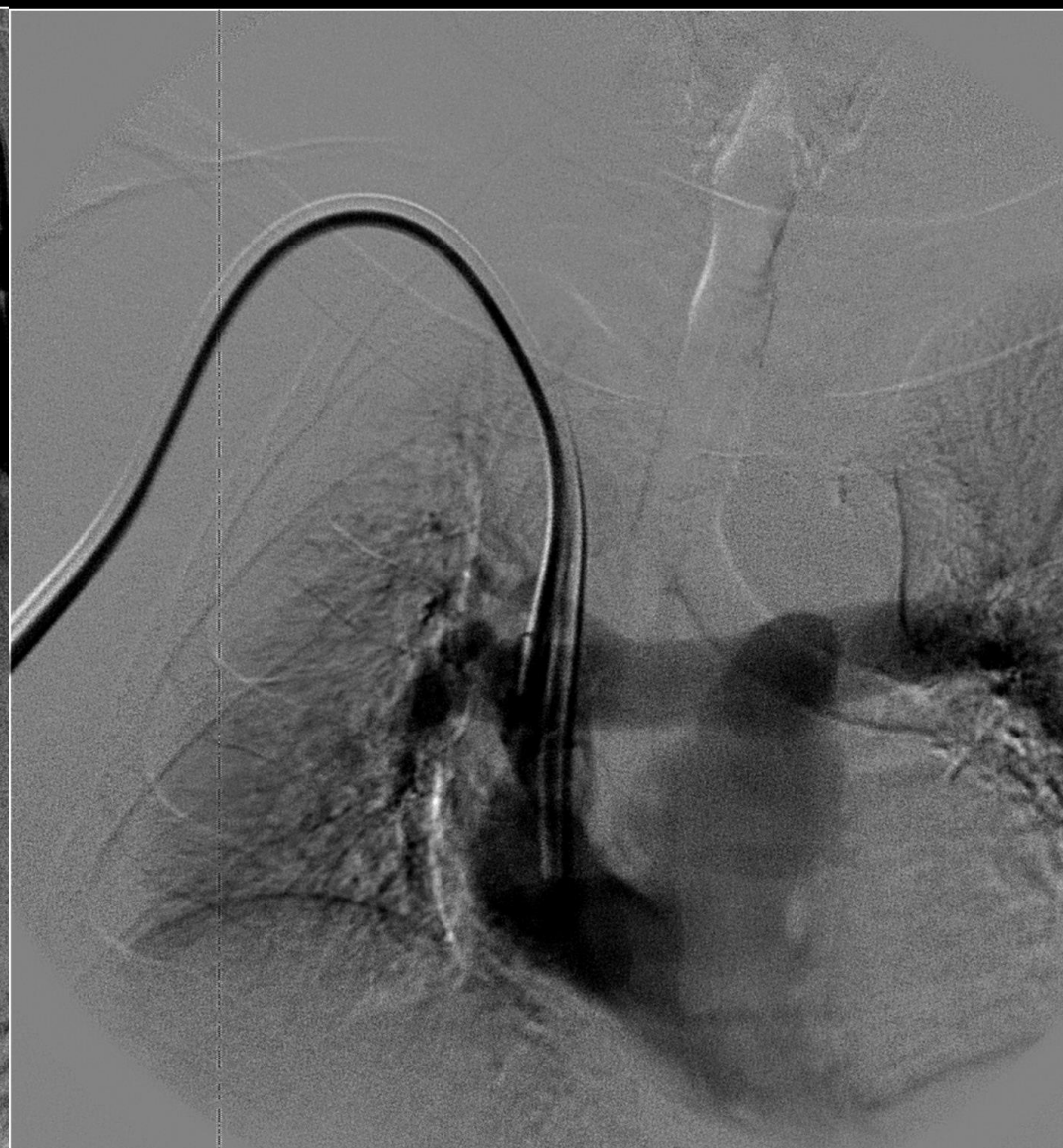
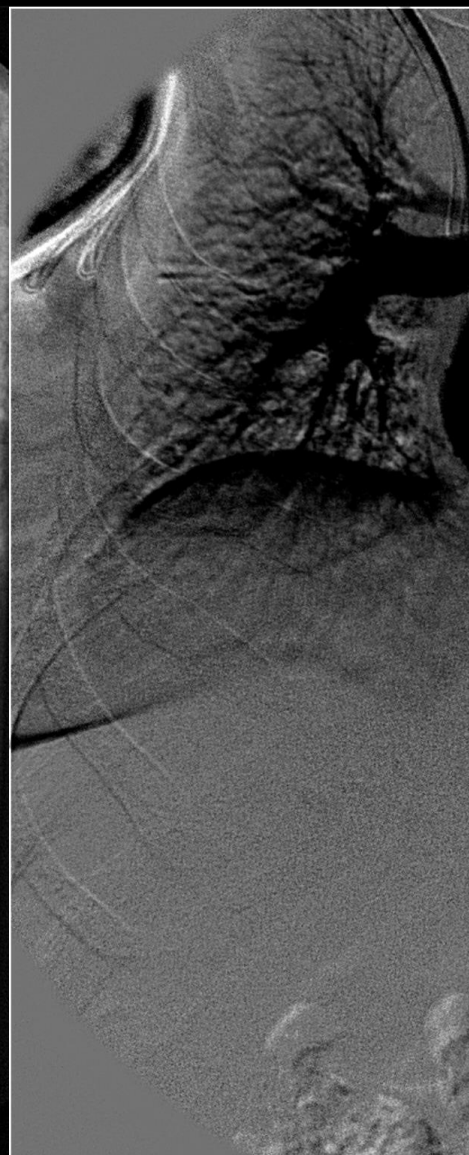
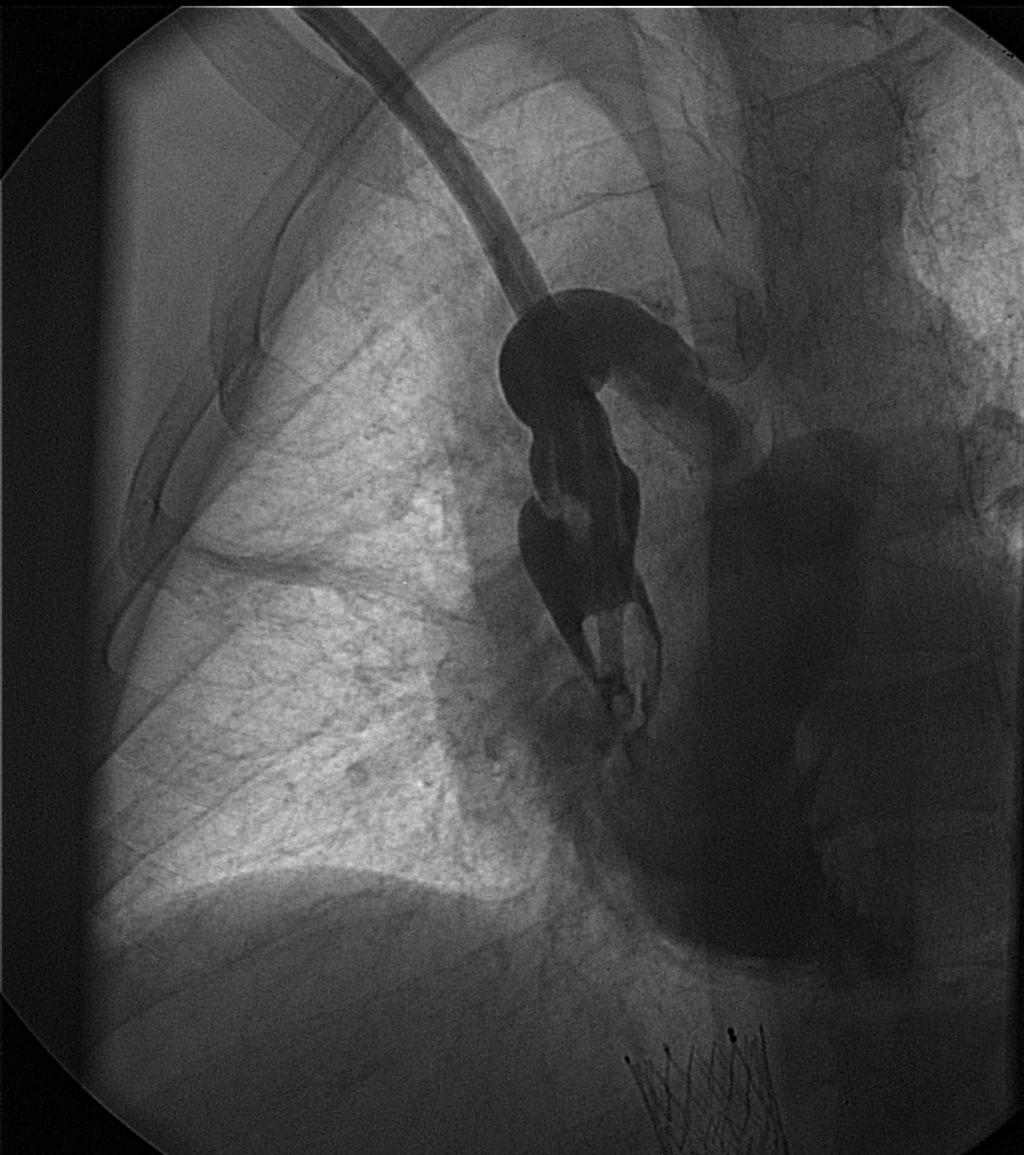NASO, CARMEN
17-06-1977
CNU@000000386
13-09-2017

T-mask: T-mask:
0.52 0.52
T-image:T-image:
5.12 5.12
T-run: T-run:
12:19:3012:39:24

T-mask:
0.52
T-image:
4.12
T-run:
12:56:57

T-image:
0.00
T-run:
12:33:37





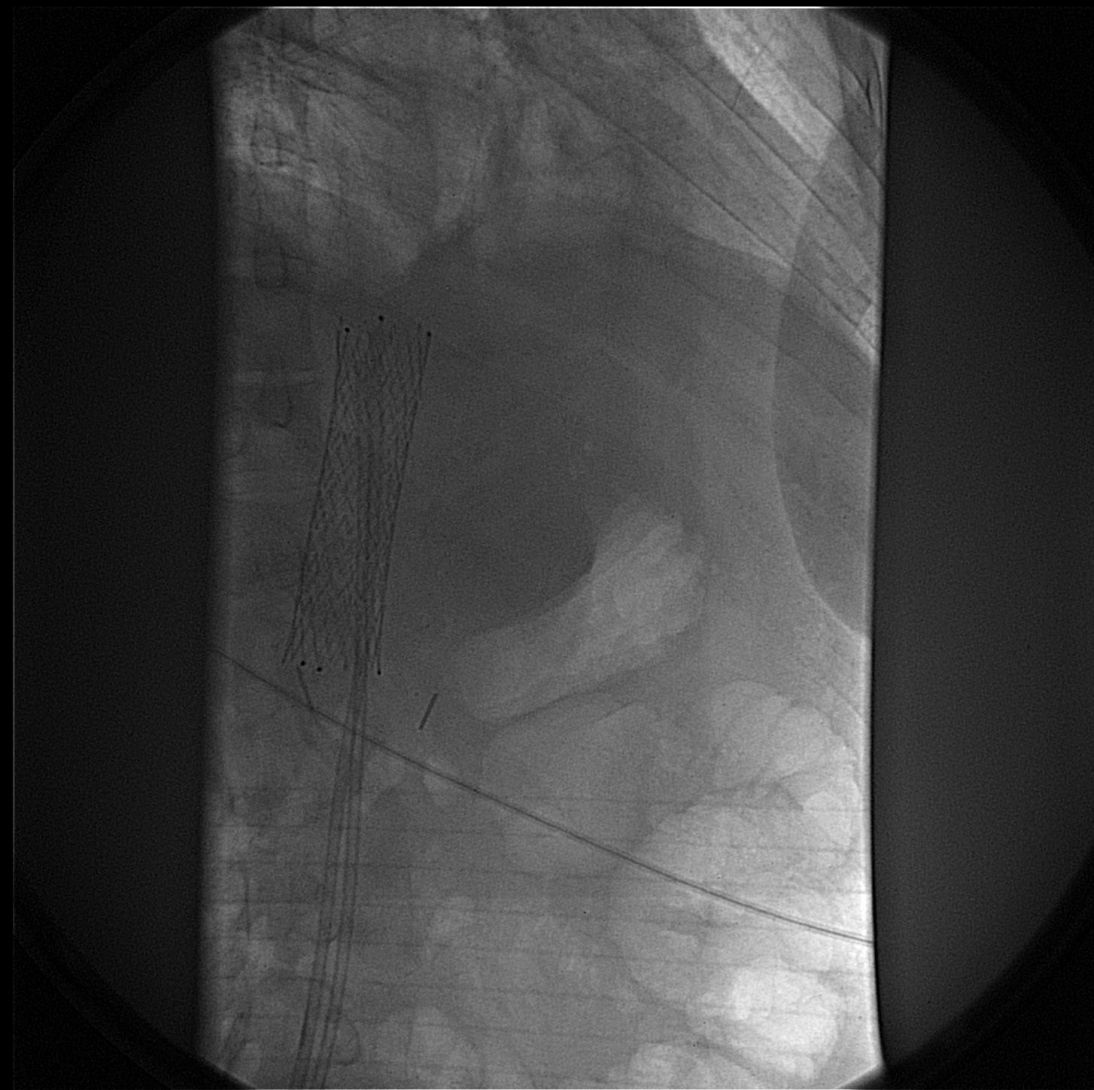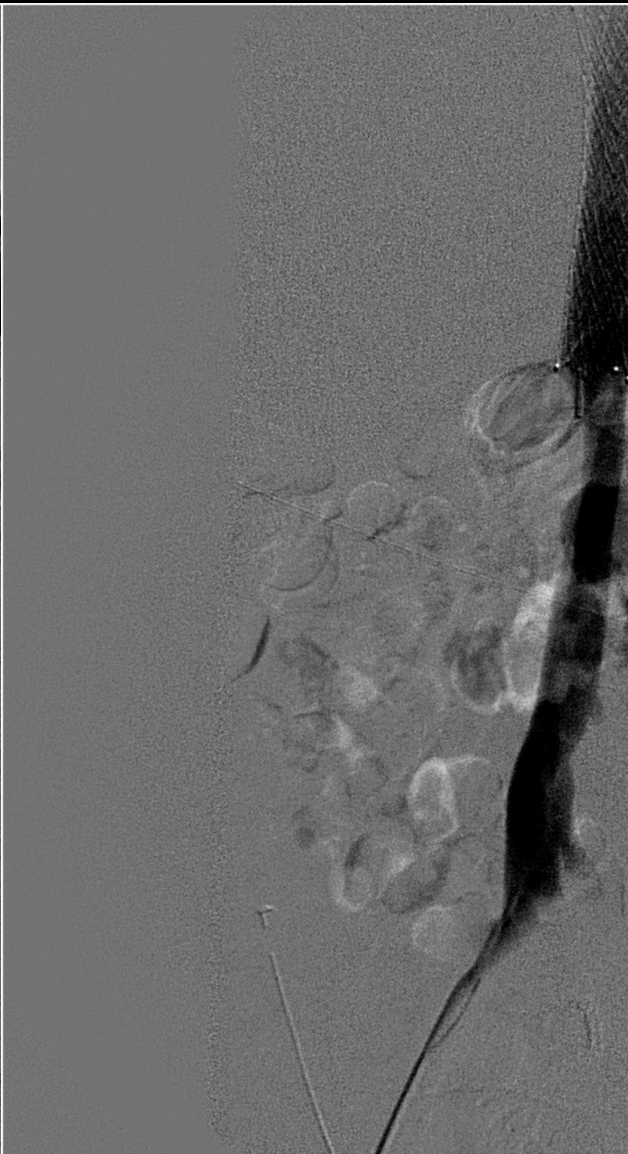
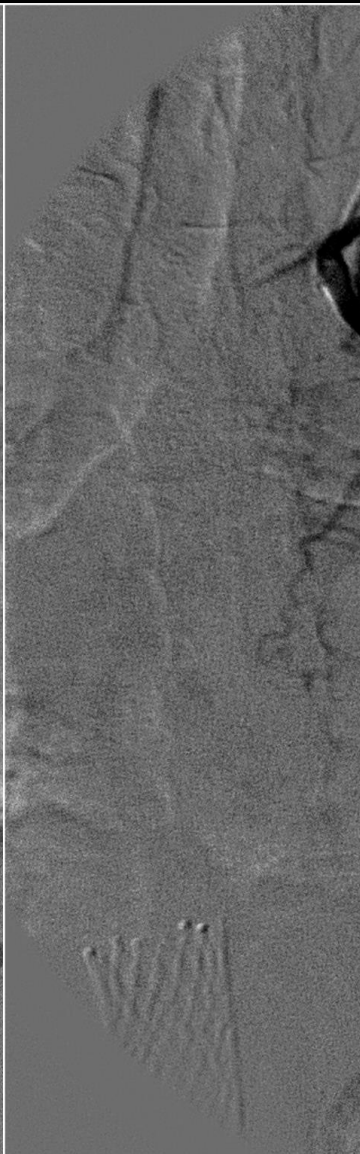
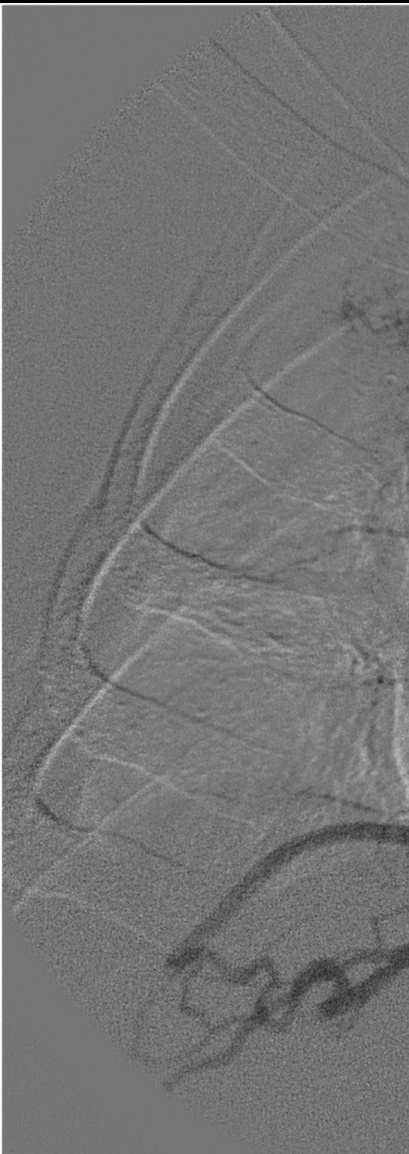
Età all'esame:
Zoom pixel: 150%
3. ▾

Età all'esame:
Zoom pixel: 150%
8. ▾

Età all'esame:
Zoom pixel: 150%
12. ▾

Età all'esame:
Zoom pixel: 141%
16. ▾

C: 512,0, W: 1024,0
C=512,0, W=1024,0 1/1



13/06/2018, 11:23:20

13/06/2018, 12:32:14


13/06/2018, 13:40:24

13/06/2018, 13:56:24

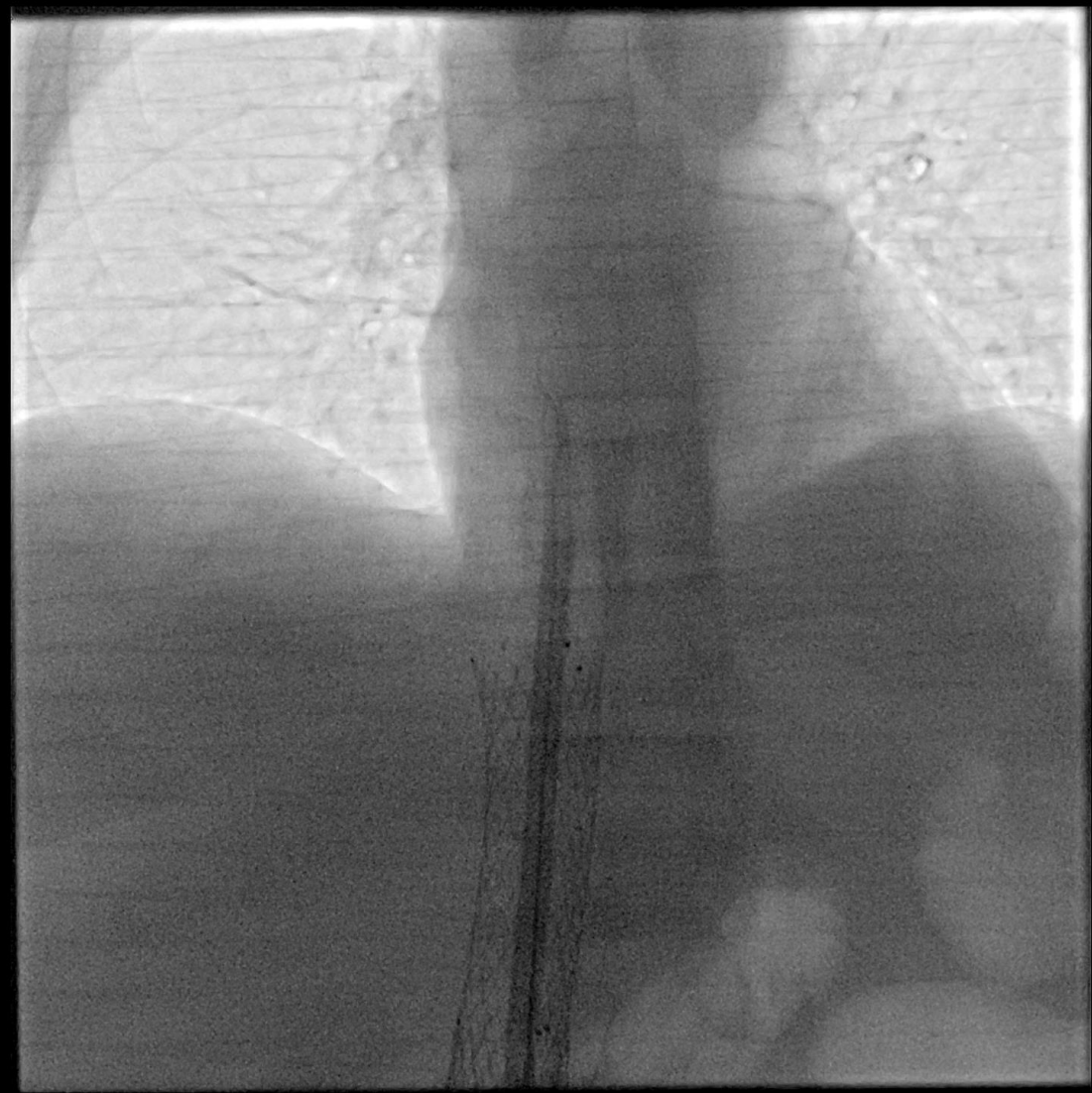


Età all'esame: Età all'esame: Età all'esame: Età all'esame: Età all'esame: Età all'esame: Età all'esame: Età all'esame: 43 anni
Zoom pixel: 120 Zoom pixel: 120% Zoom pixel: 120% Zoom pixel: 120% Zoom pixel: 150% Zoom pixel: 150% Zoom pixel: 138% REF
1. ▾ 1. ▾ 1. ▾ 1. ▾ 25. ▾ 20. ▾ 3. ▾ Zoom pixel: 150%
1. FL(-) Torace sharp ▾

C: 2047,0, W: 4095,0
C=2047,0, W=4095,0 1/1
#

NASO, CARM
17-06-197
CNU@000000
18-06-201



T-mask:
0.52
T-image:
3.12
T-run:
11:46:47



18/06/2019, 18/06/2019, 10: 18/06/2019, 10: 18/06/2019, 10:5 18/06/2019, 12:42:11 18/06/2019, 12: 23/01/2020 09/04/2021. 13:18:23

F

OMMMM



